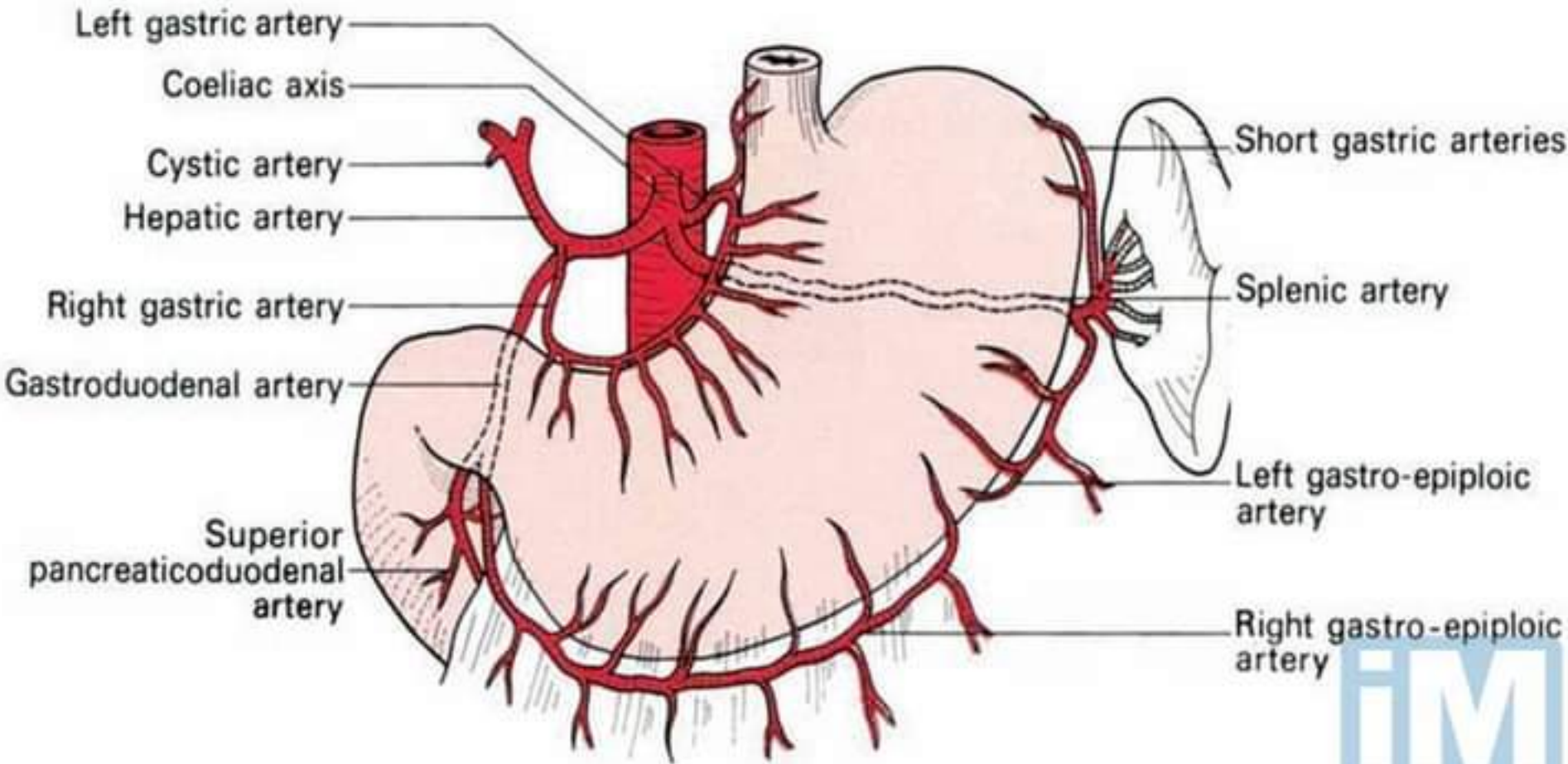
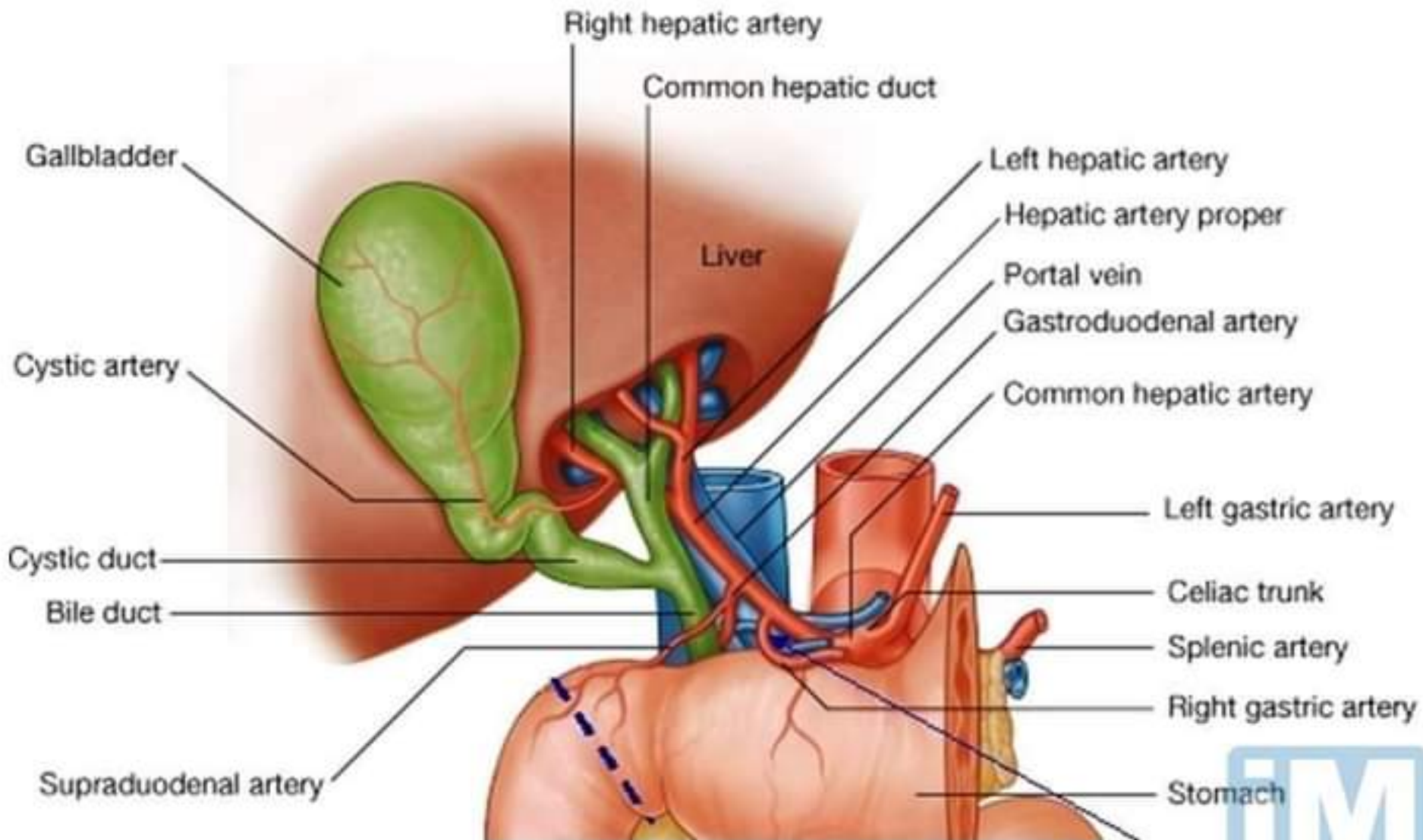


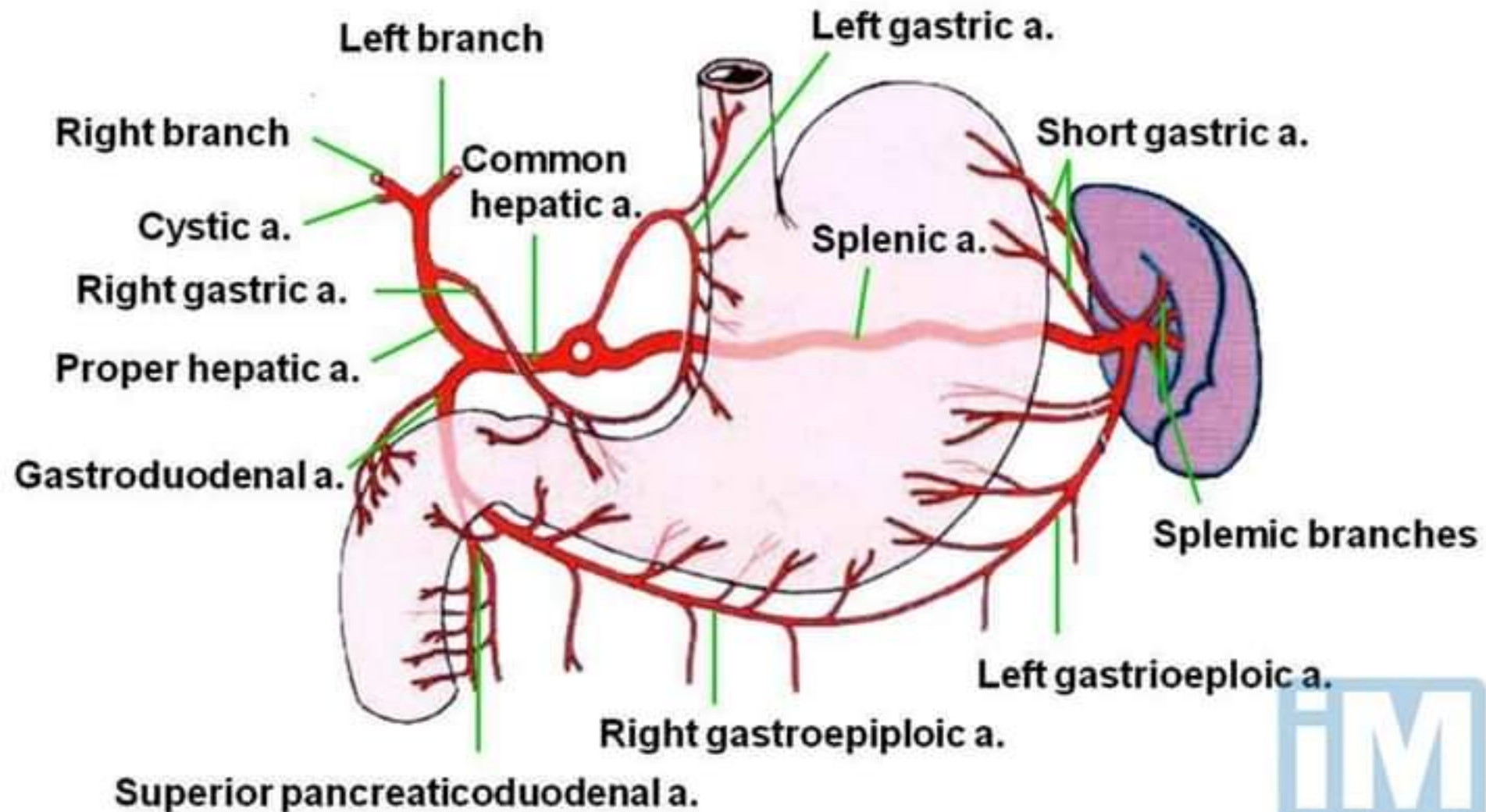
Blood supply of the Stomach



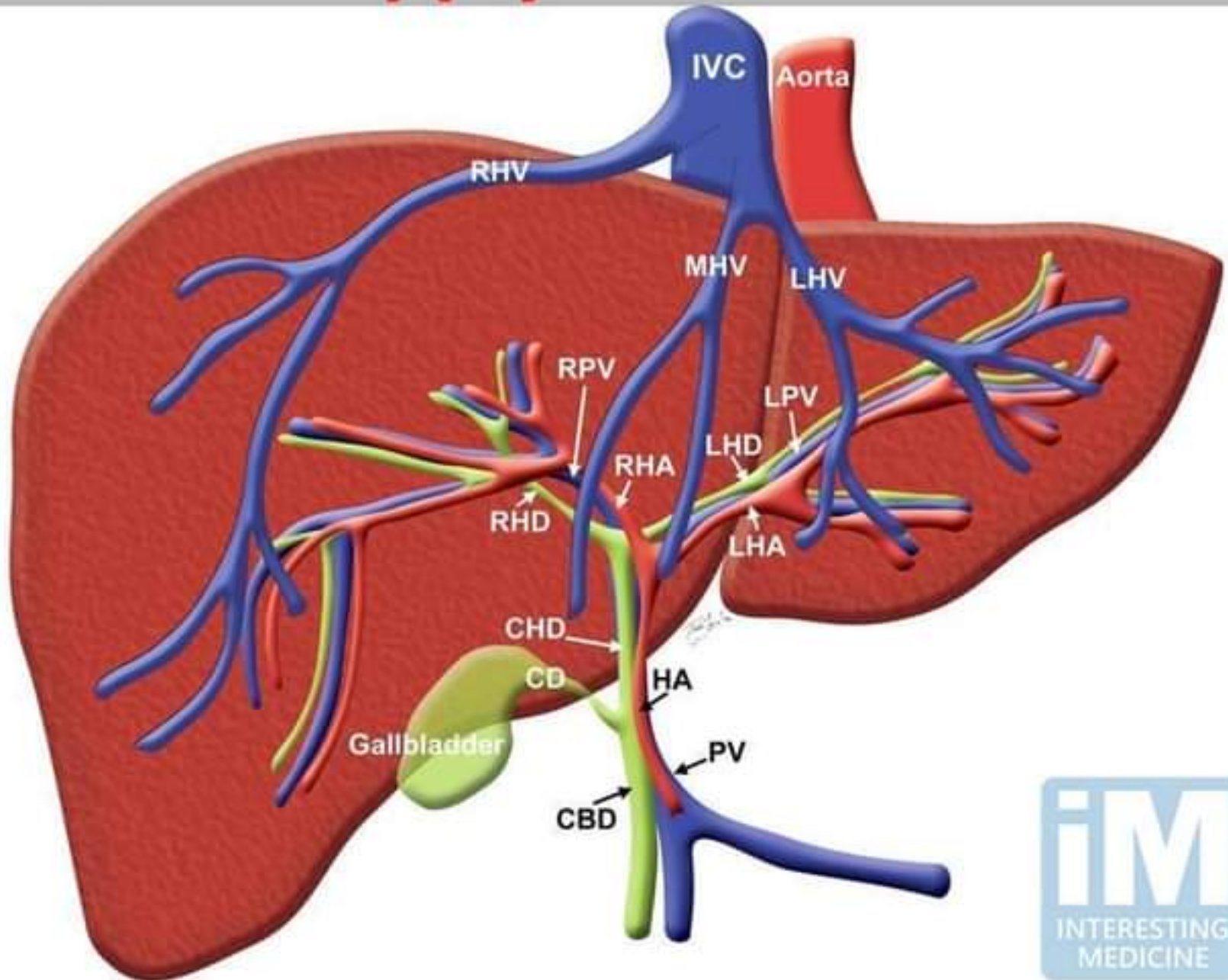
Coeliac artery/Coeliac axis



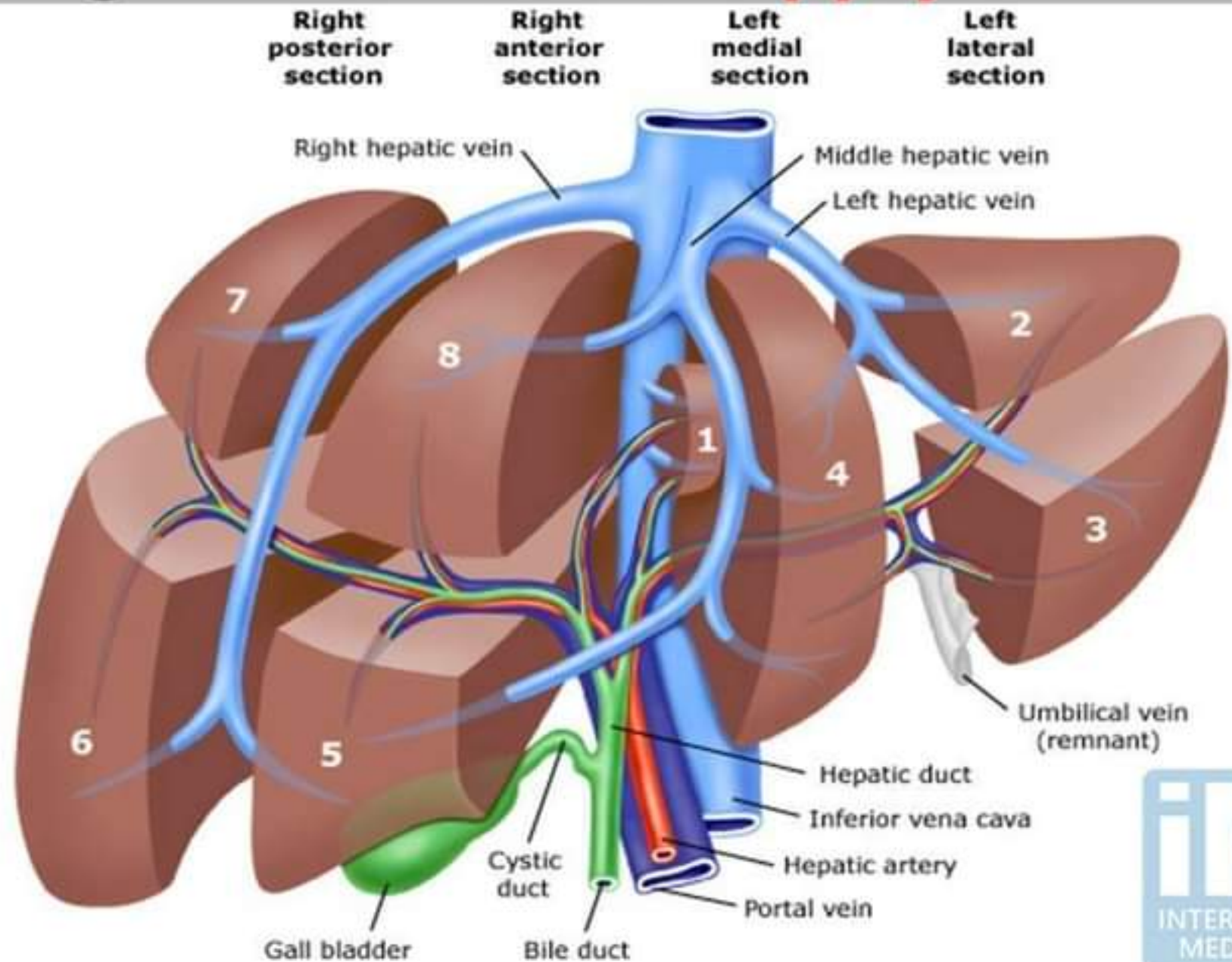
Coeliac artery/Coeliac axis



Blood supply of the liver

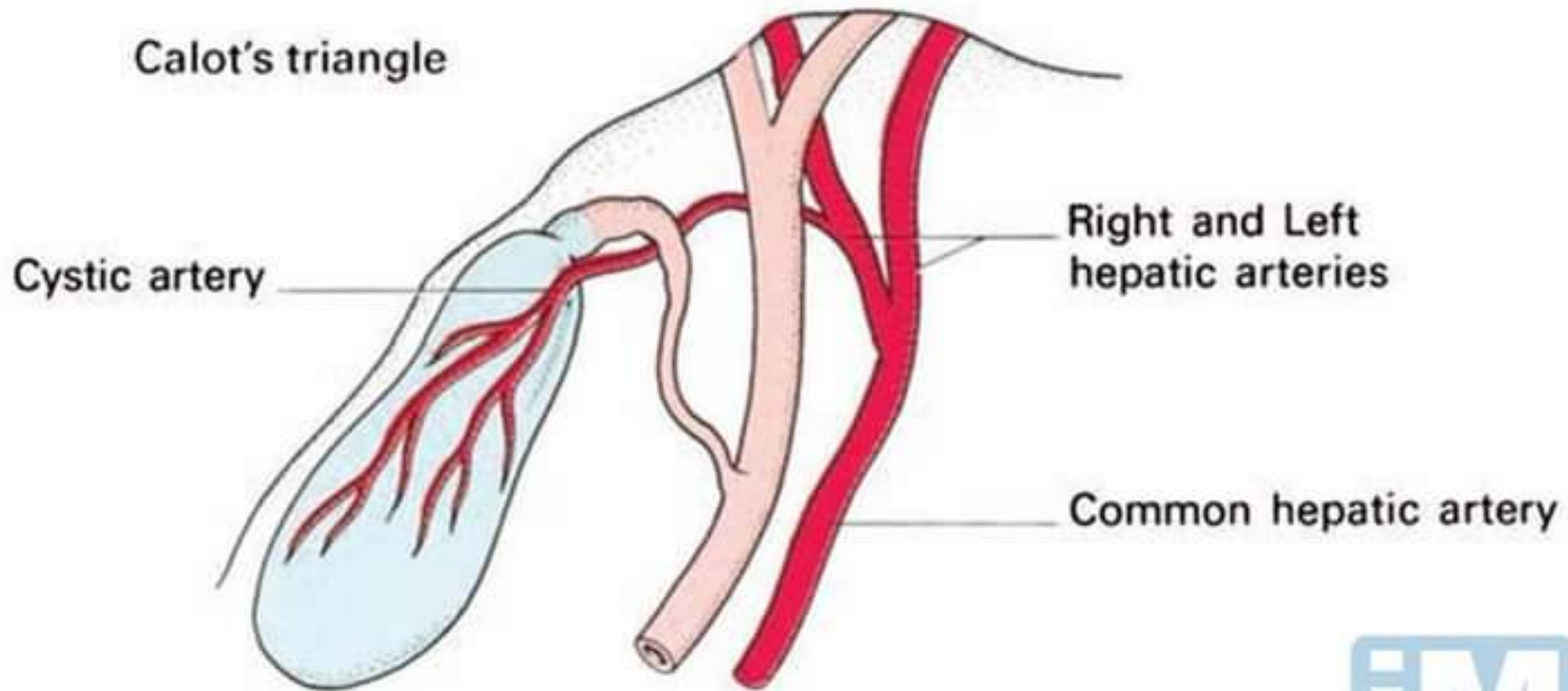


Segmental **blood supply** of Liver

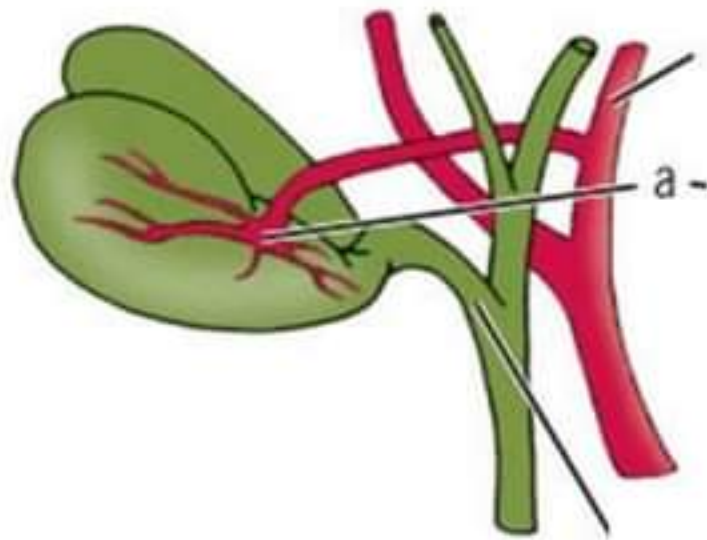


Blood supply of the Gall bladder

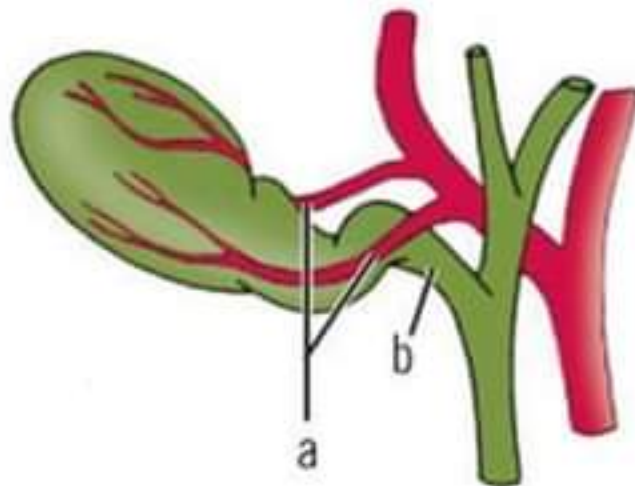
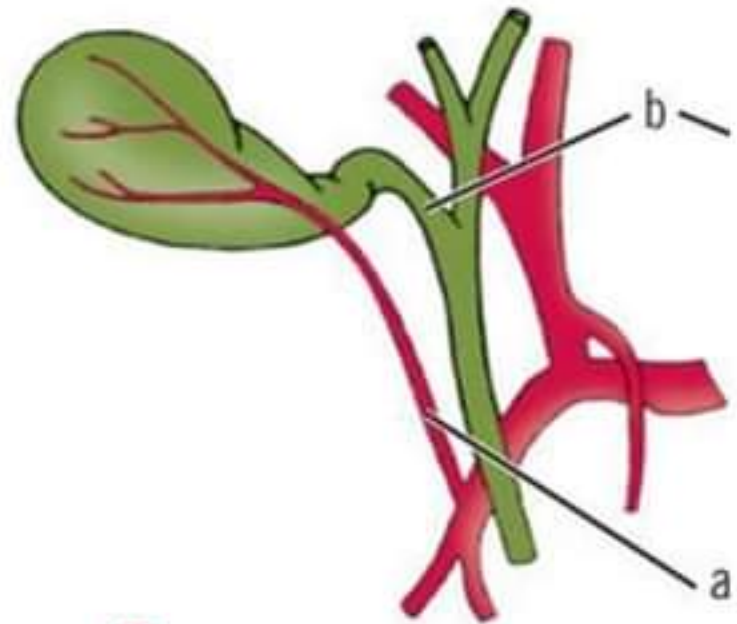
Calot's triangle



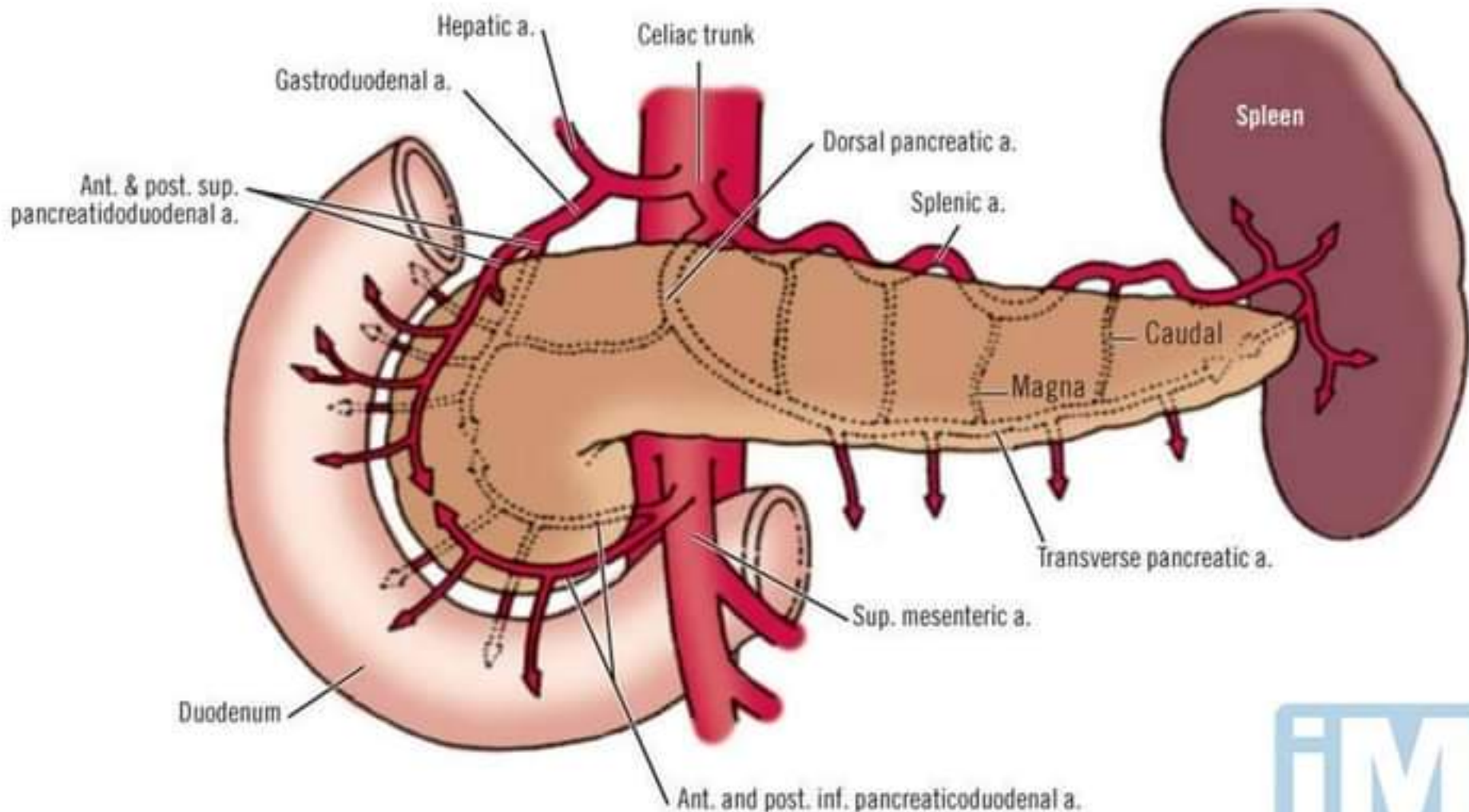
Abnormal origin of Cystic artery



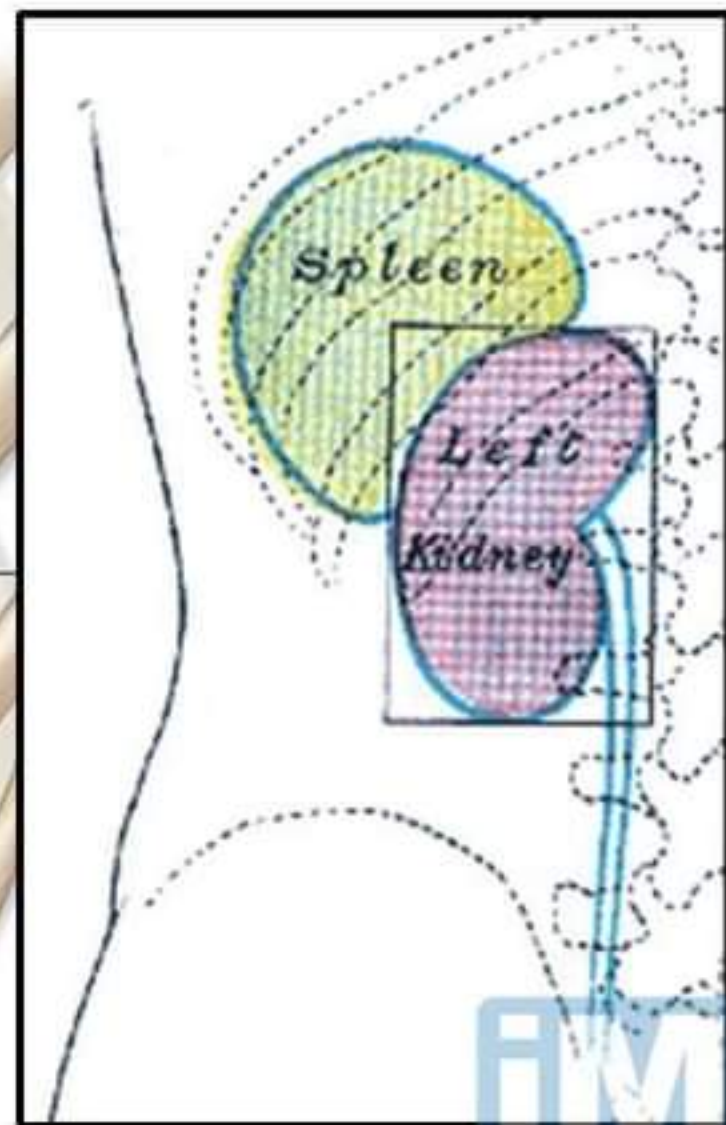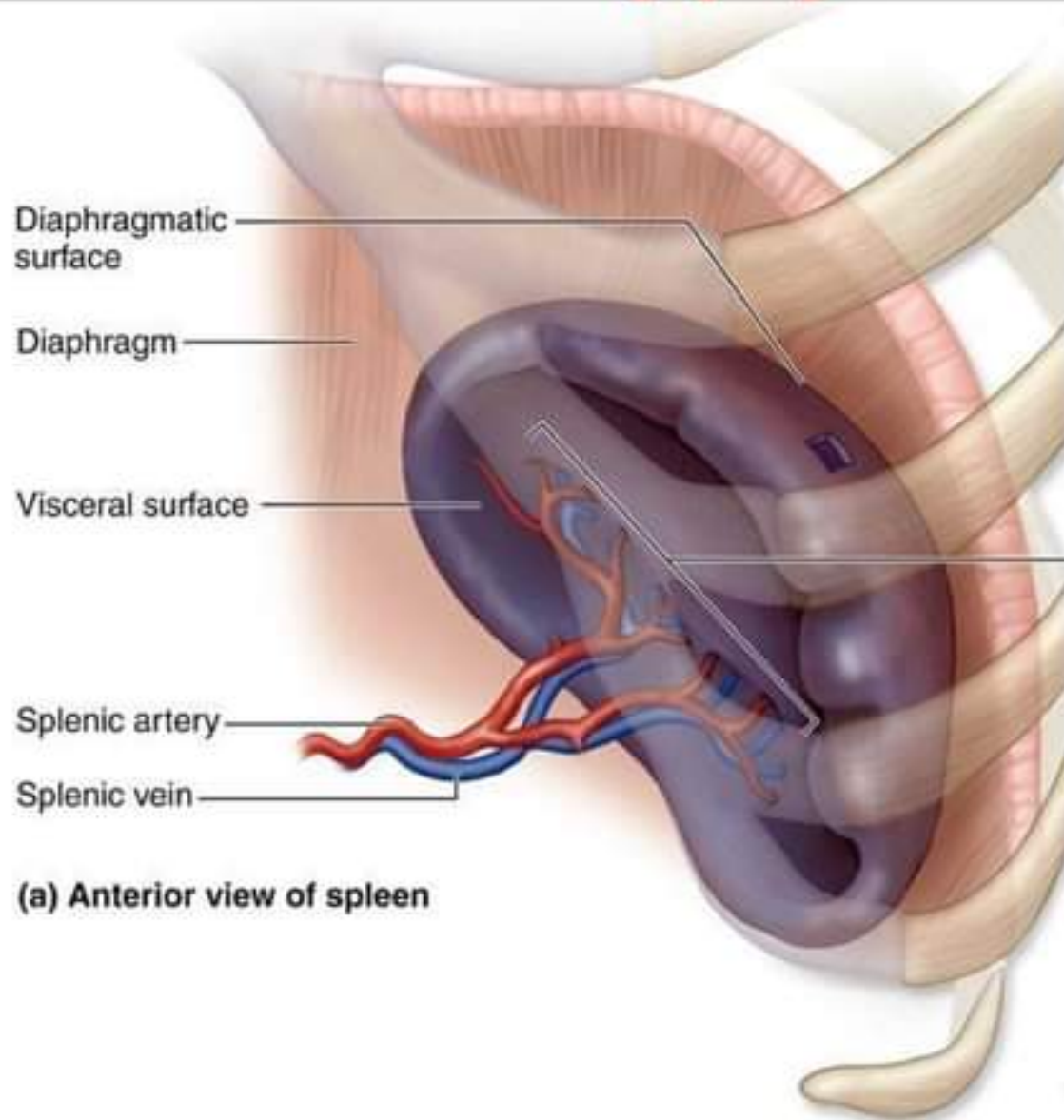
A



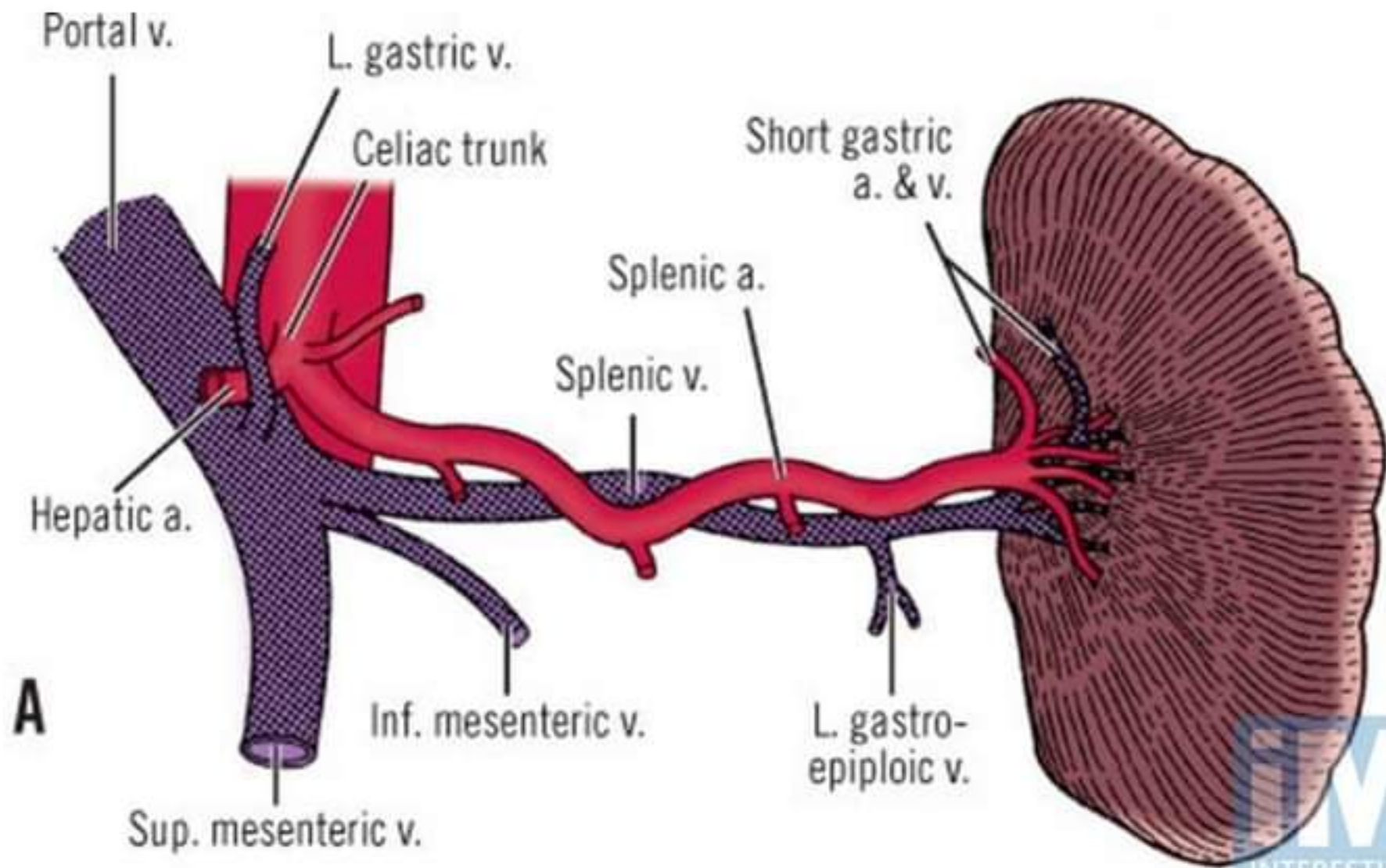
Blood supply of the Pancreas



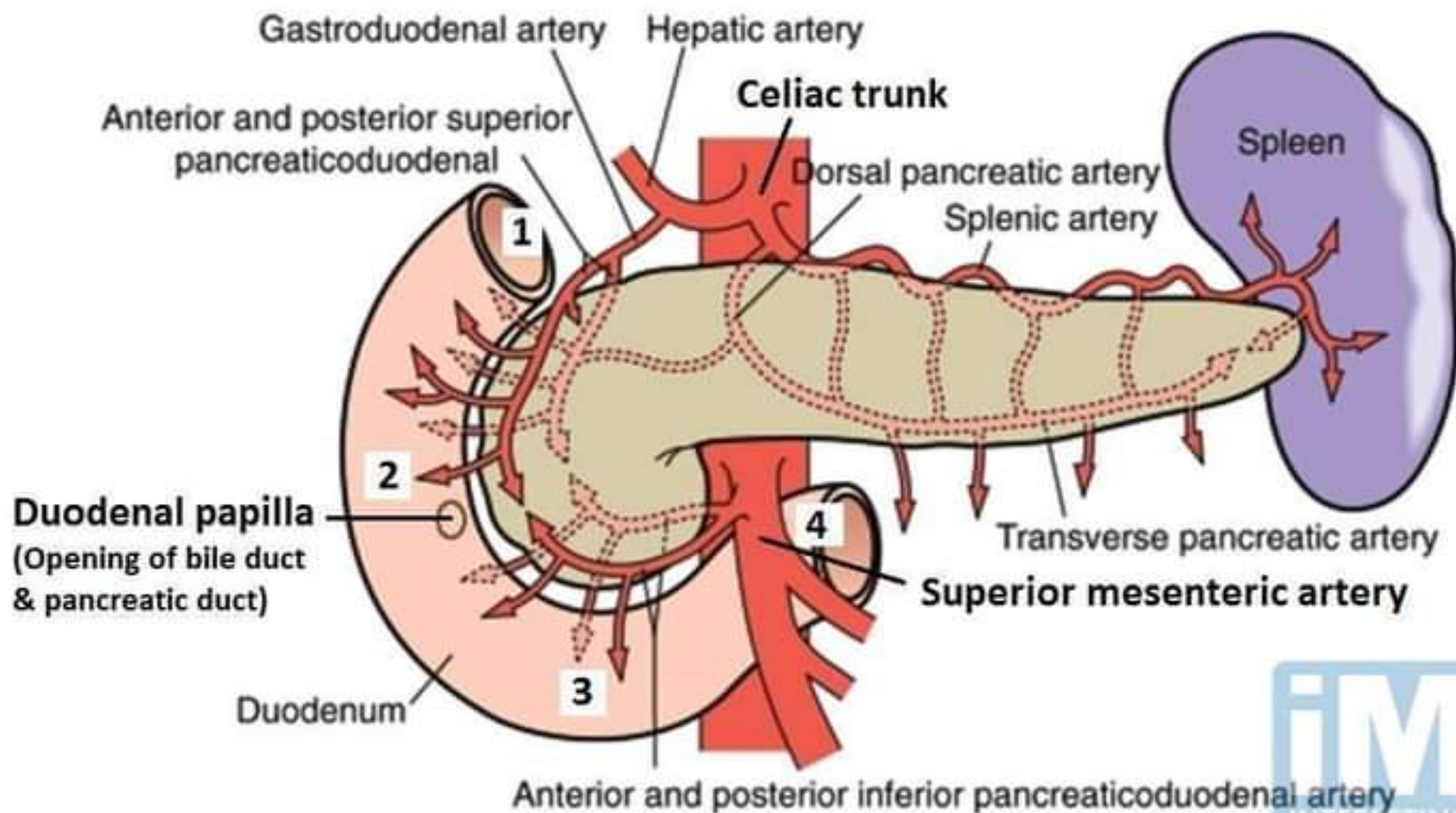
Blood supply of the Spleen



Splenic artery and vein

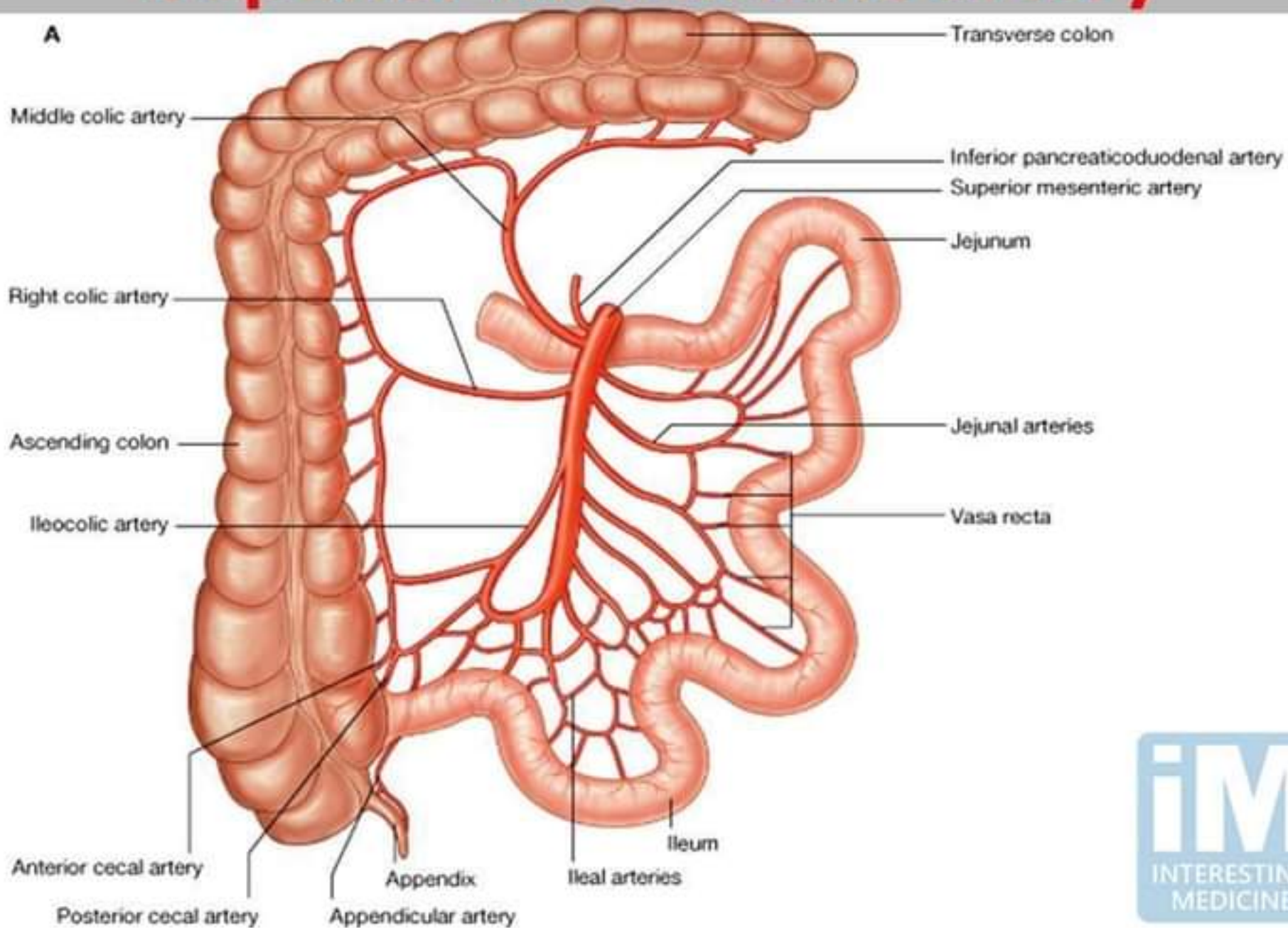


Arterial supply of the duodenum

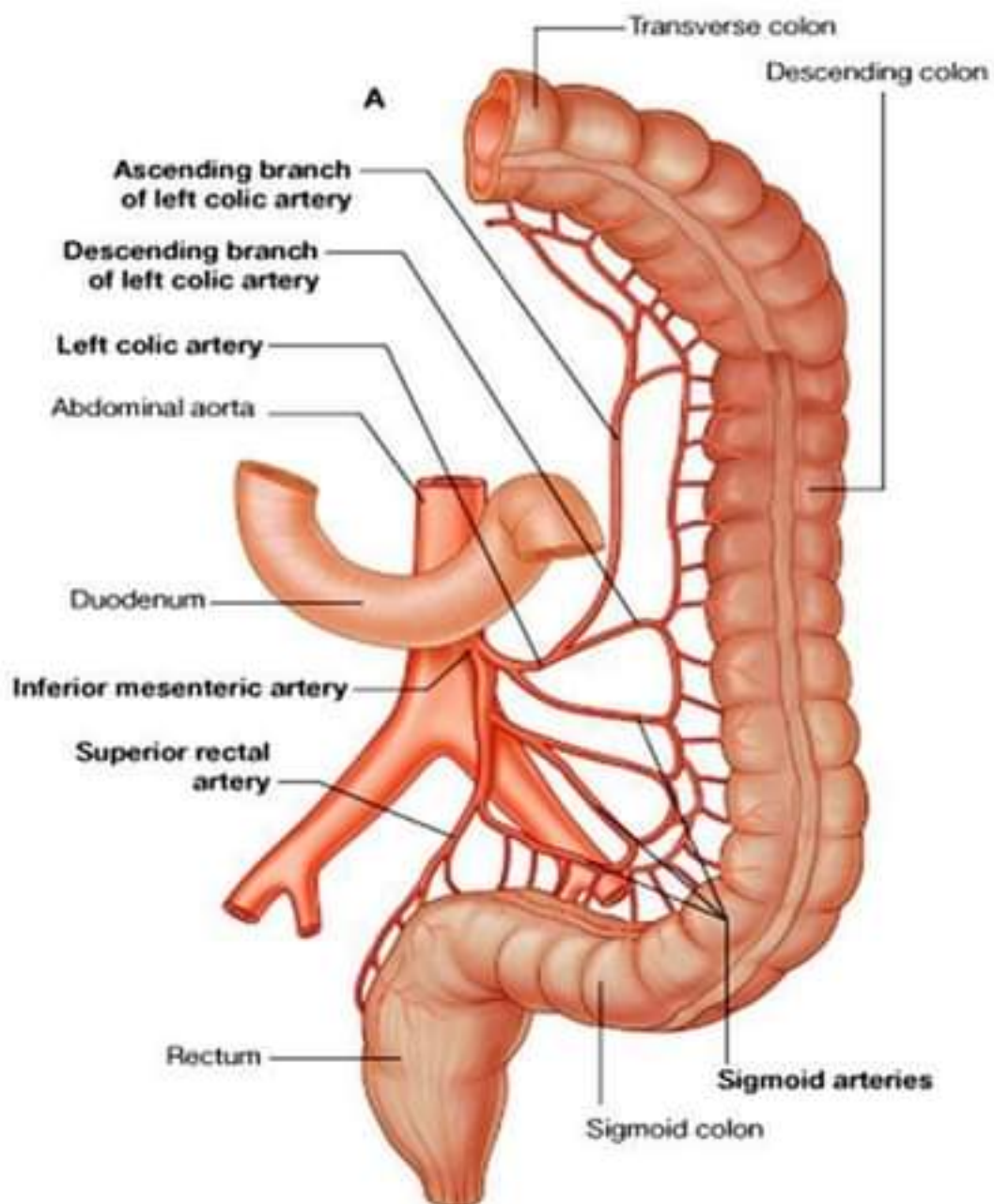


Superior mesenteric artery

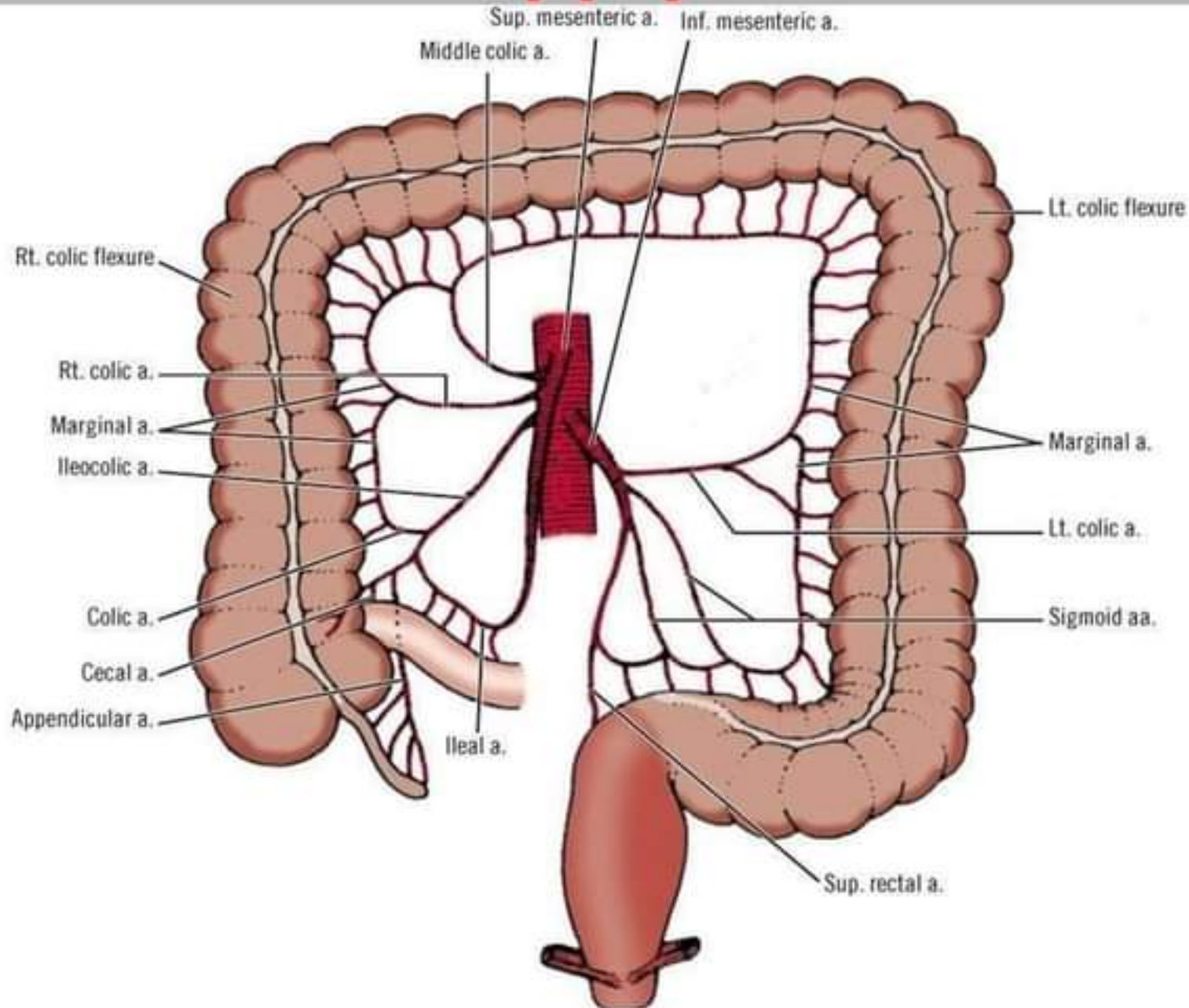
A



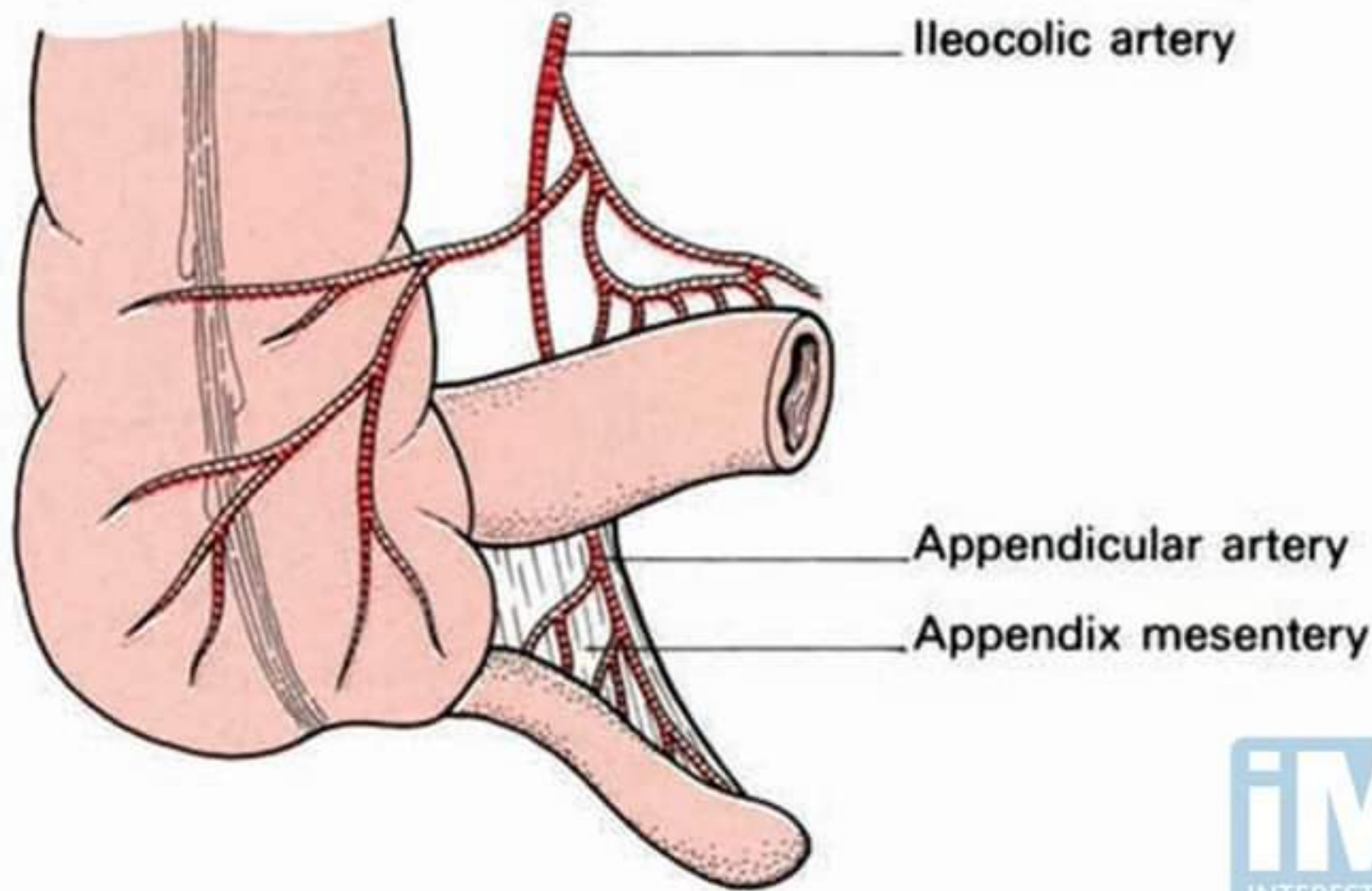
Inferior mesenteric artery



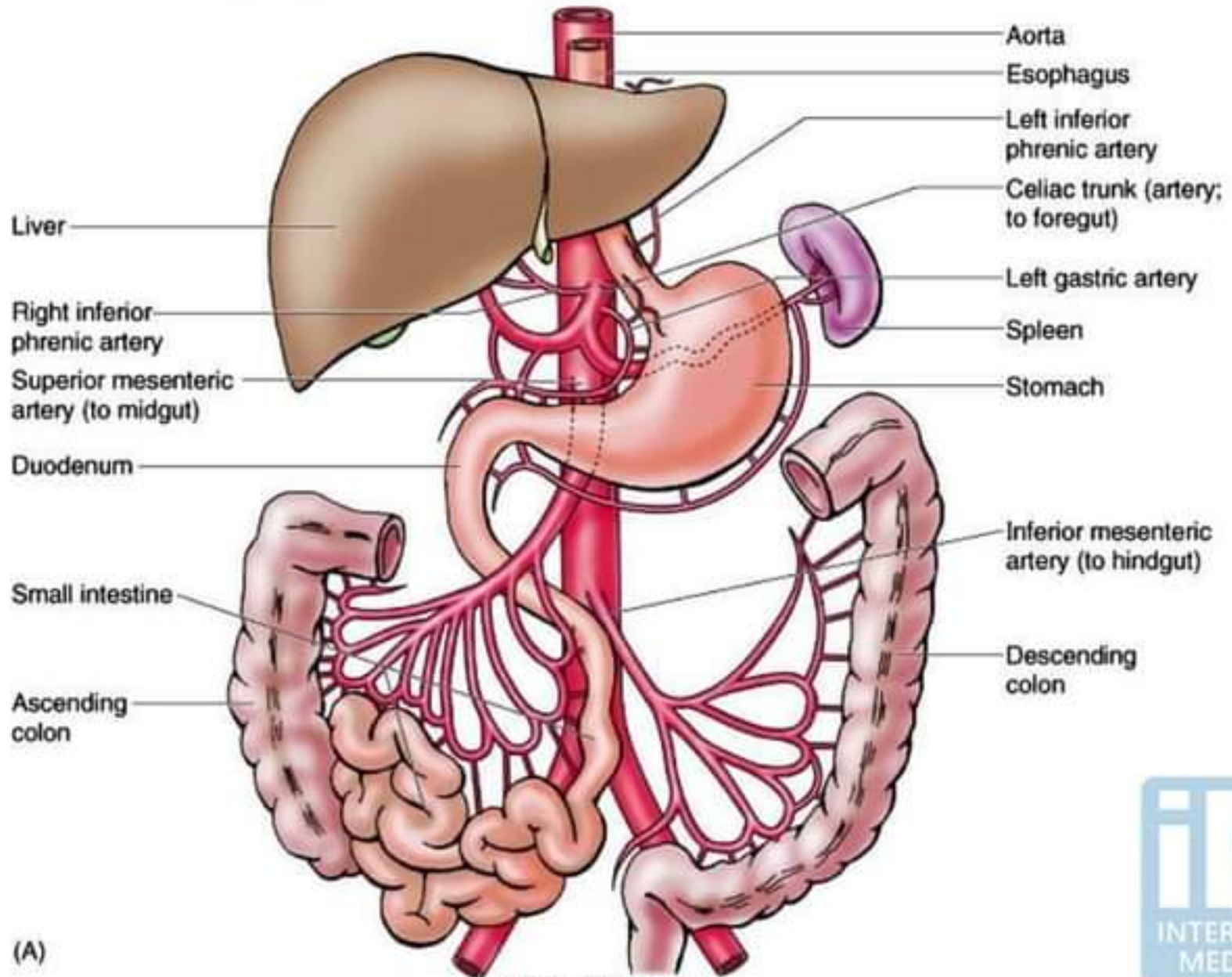
Blood supply of the Colon



Blood supply of the Appendix

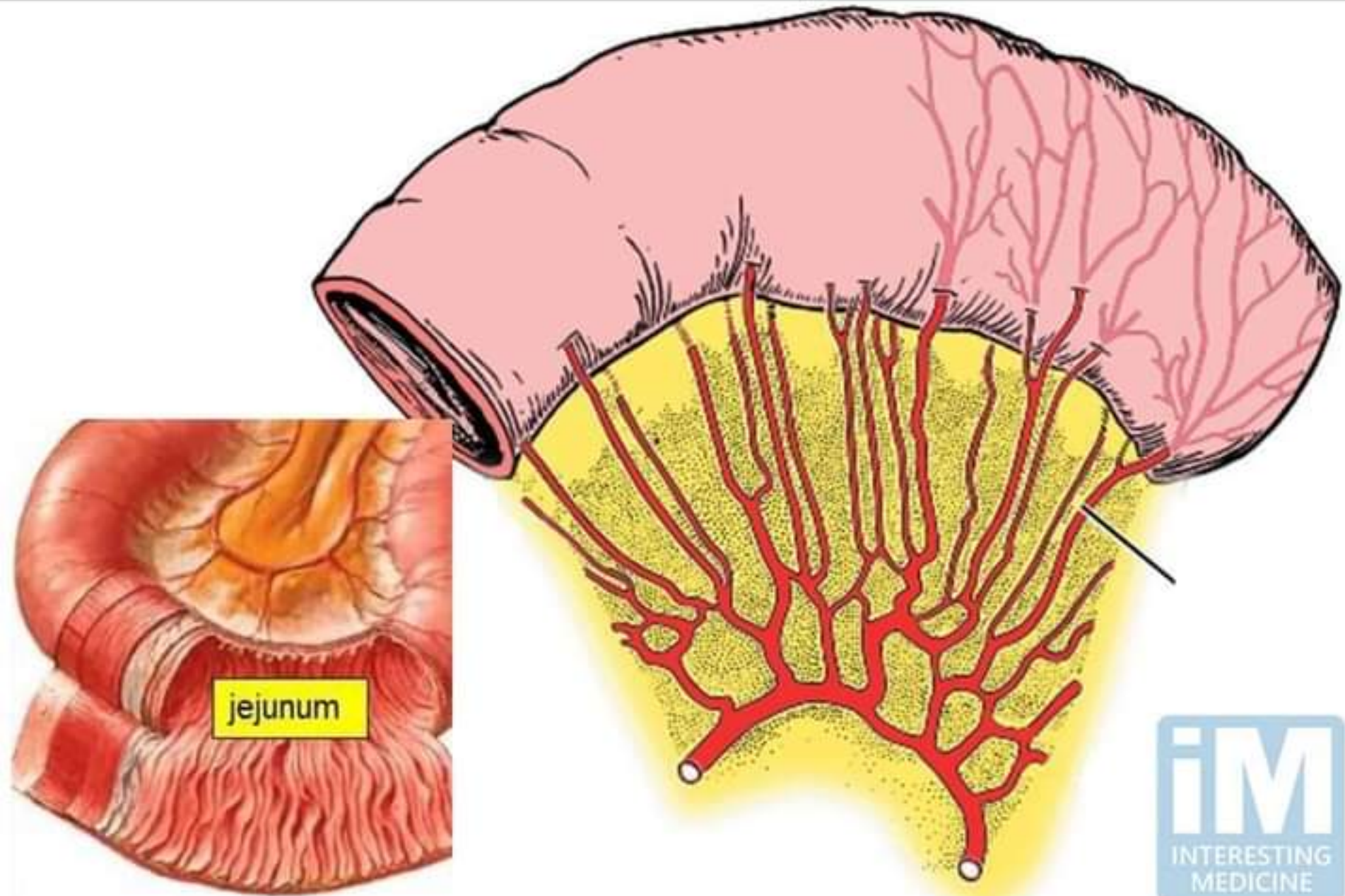


Blood supply of the Gastrointestinal tract

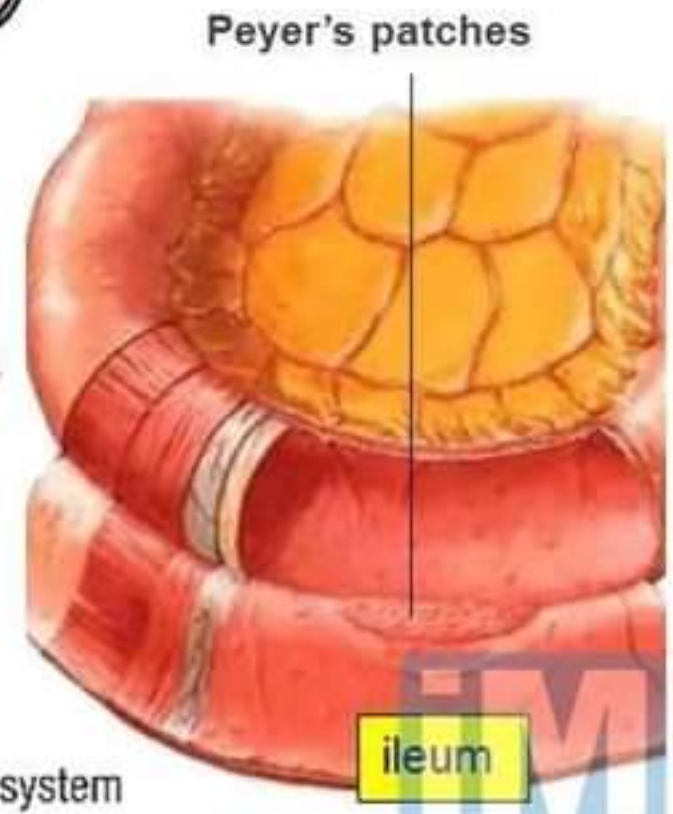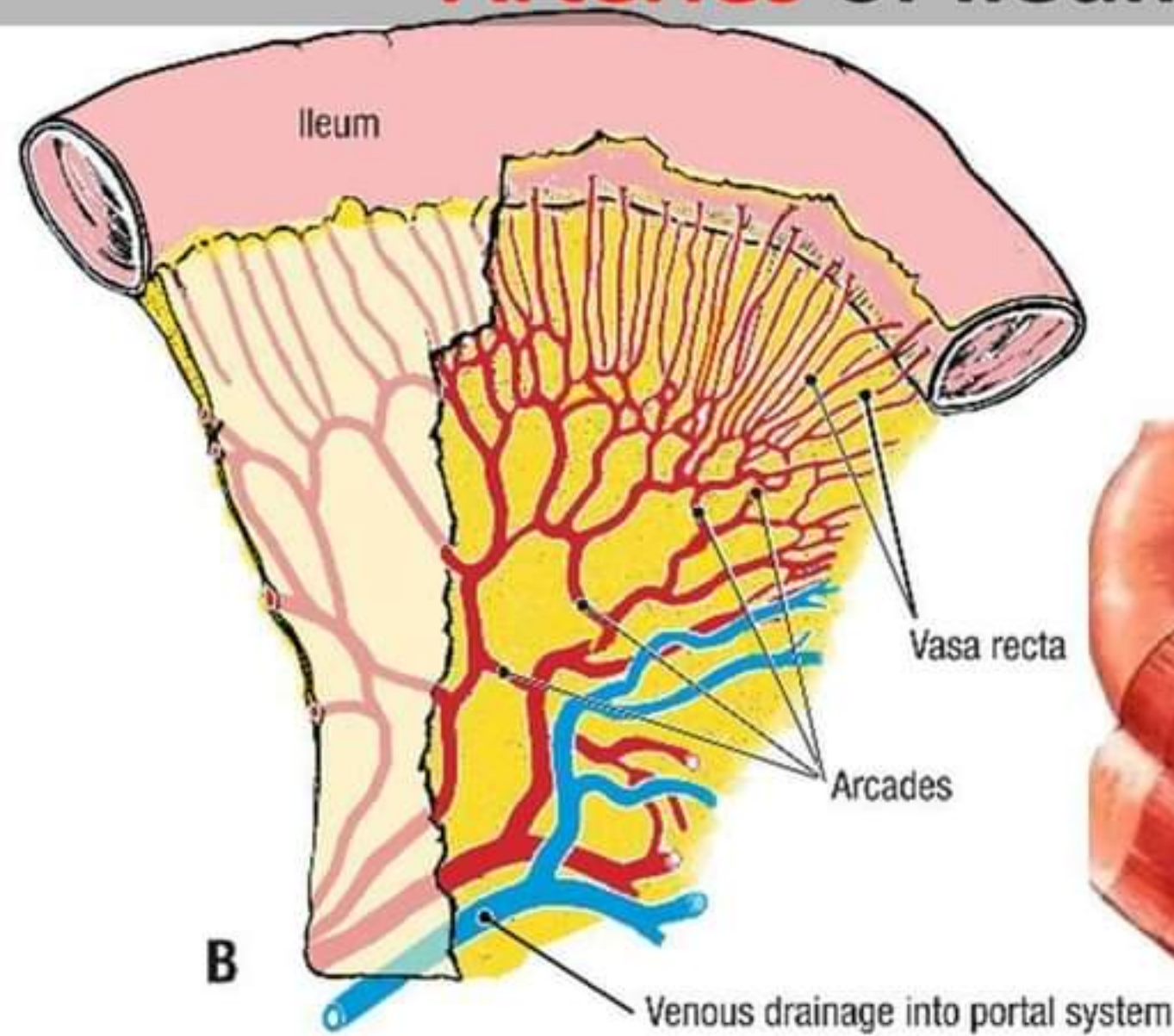


(A)

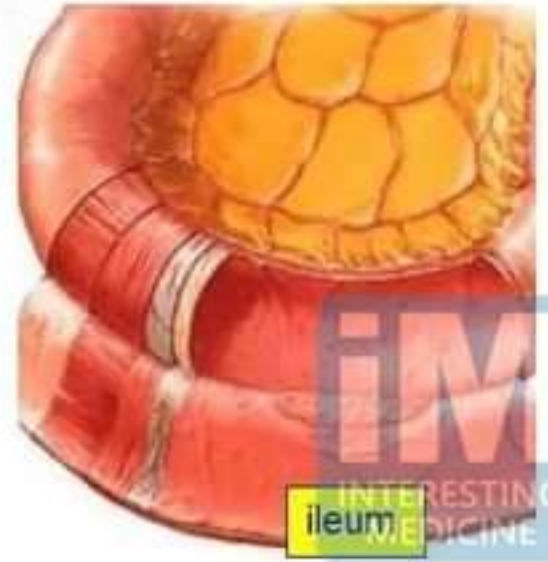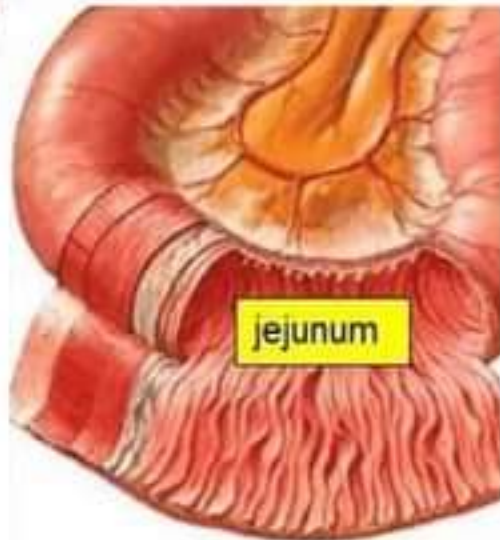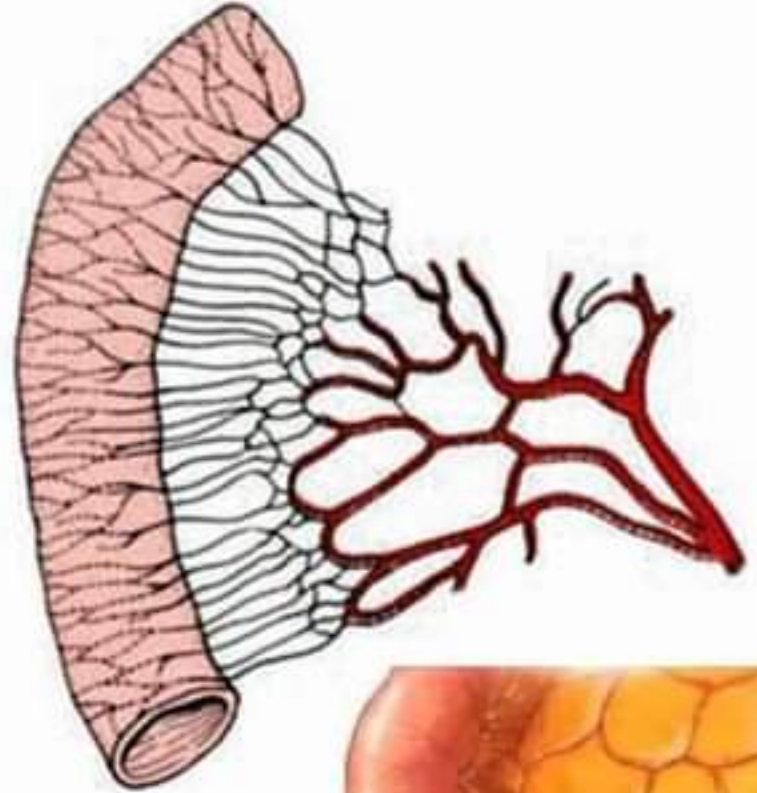
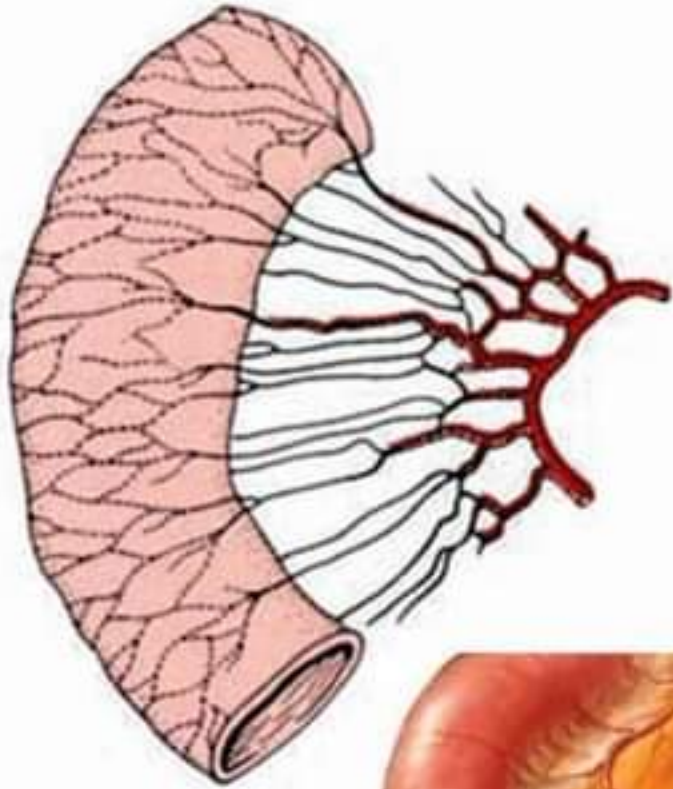
Arteries of Jejunum



Arteries of Ileum



Jejunum Vs. Ileum



Portal Venous system

