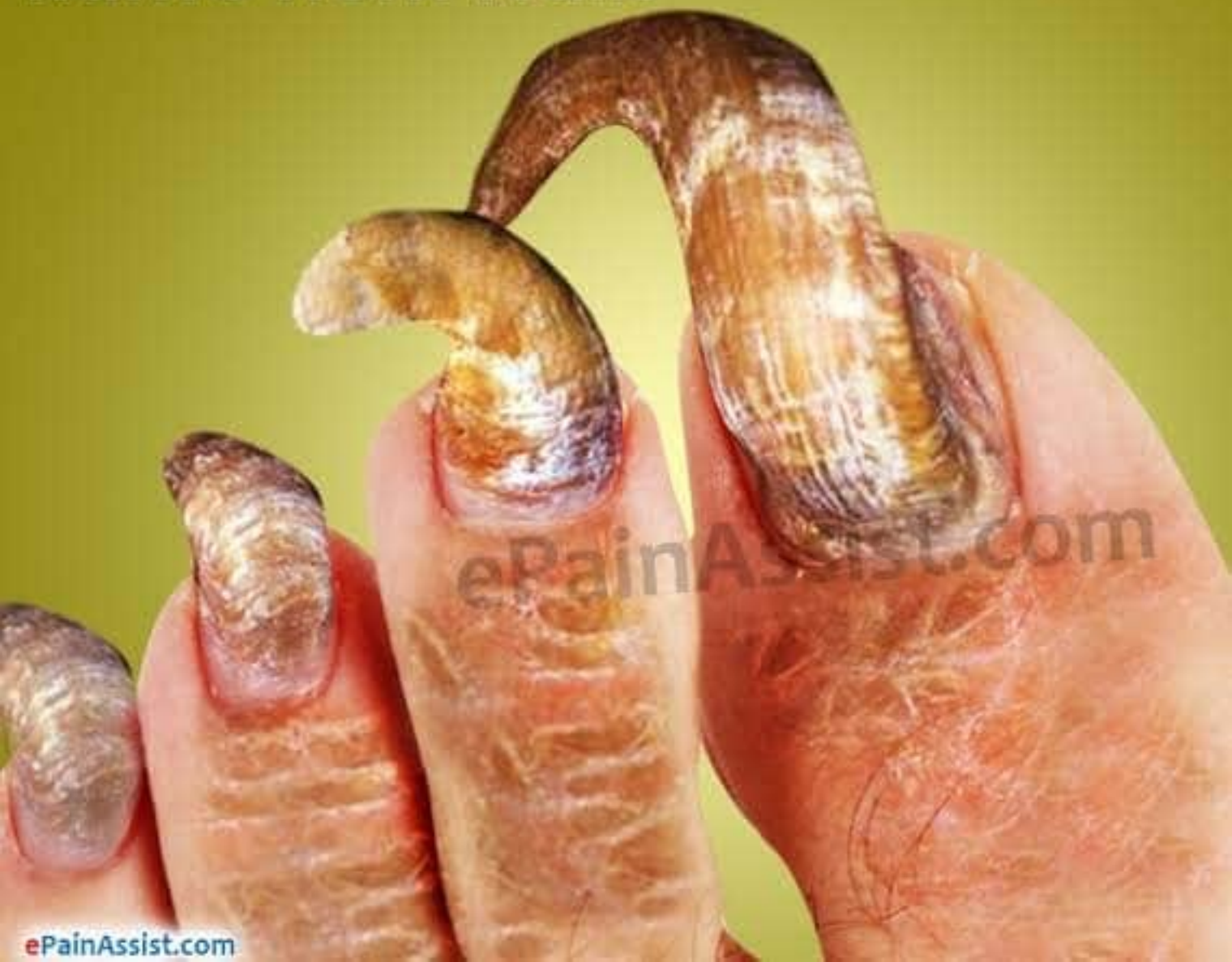
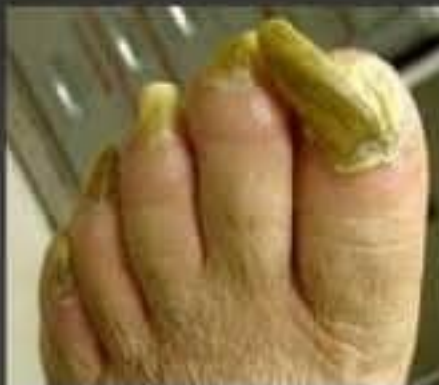
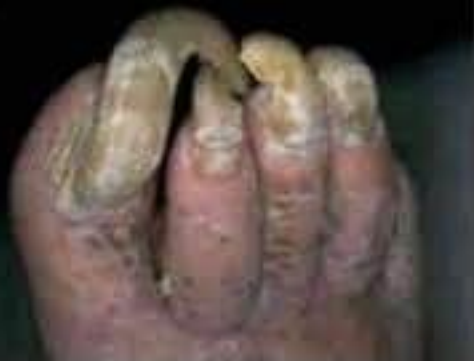Onychogryphosis or Ram's Horn Nails

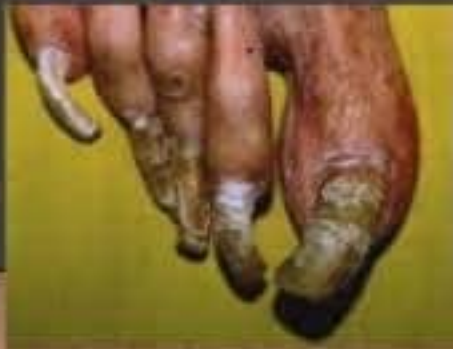
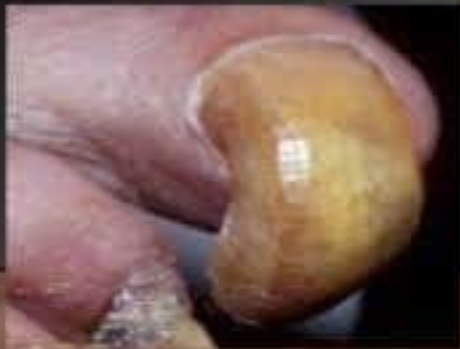
Onychogryphosis

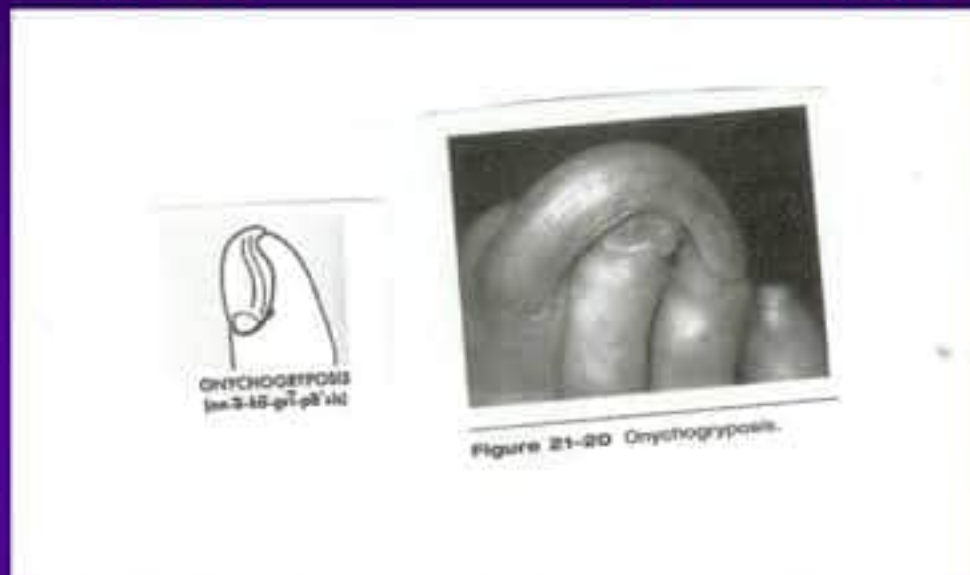


ONYCHOGRYPHOSIS OR CLAW NAILS

- It pertains to extreme thickening curvature of the nails, usually it is caused by varying degree of hyperkeratosis (skin disease in which the skin gets thicker) on the distal portion of the nail bed that detaches and lifts the plate off the bed



Onychogryposis – onychogryphosis




- ◆ Thickening and increased curvature of the nail
- ◆ Also called “ram’s horn nail” and is usually the result of injury to the matrix
- ◆ May be hereditary and can also occur as the result of long-term neglect

Onychogryphosis

- “Claw nail” or “Rams Horn Nail”
 - Disease causes curvature of the nail
 - Disease causes thickening of the nail
- Etiology
 - Injury: dropping heavy objects or hitting toe
 - Intense pressure over long periods of time: footwear
 - Fungal infection
 - Diabetes
 - Peripheral vascular disease
 - Nutritional
 - Other conditions such as psoriasis, epidermal dysplasia & ichthyosis

Symptoms of Onychogryphosis

- 
- The nail gradually becomes thick, long and deformed as they increase in length
 - There can be yellowish discoloration to the nail
 - The nail plate also becomes thick and tender
 - Pain or discomfort in the affected nails upon pressure
 - Nails which are long and curved can affect the adjacent toes resulting in more pain and infection.

For More Information, Visit: www.epainassist.com