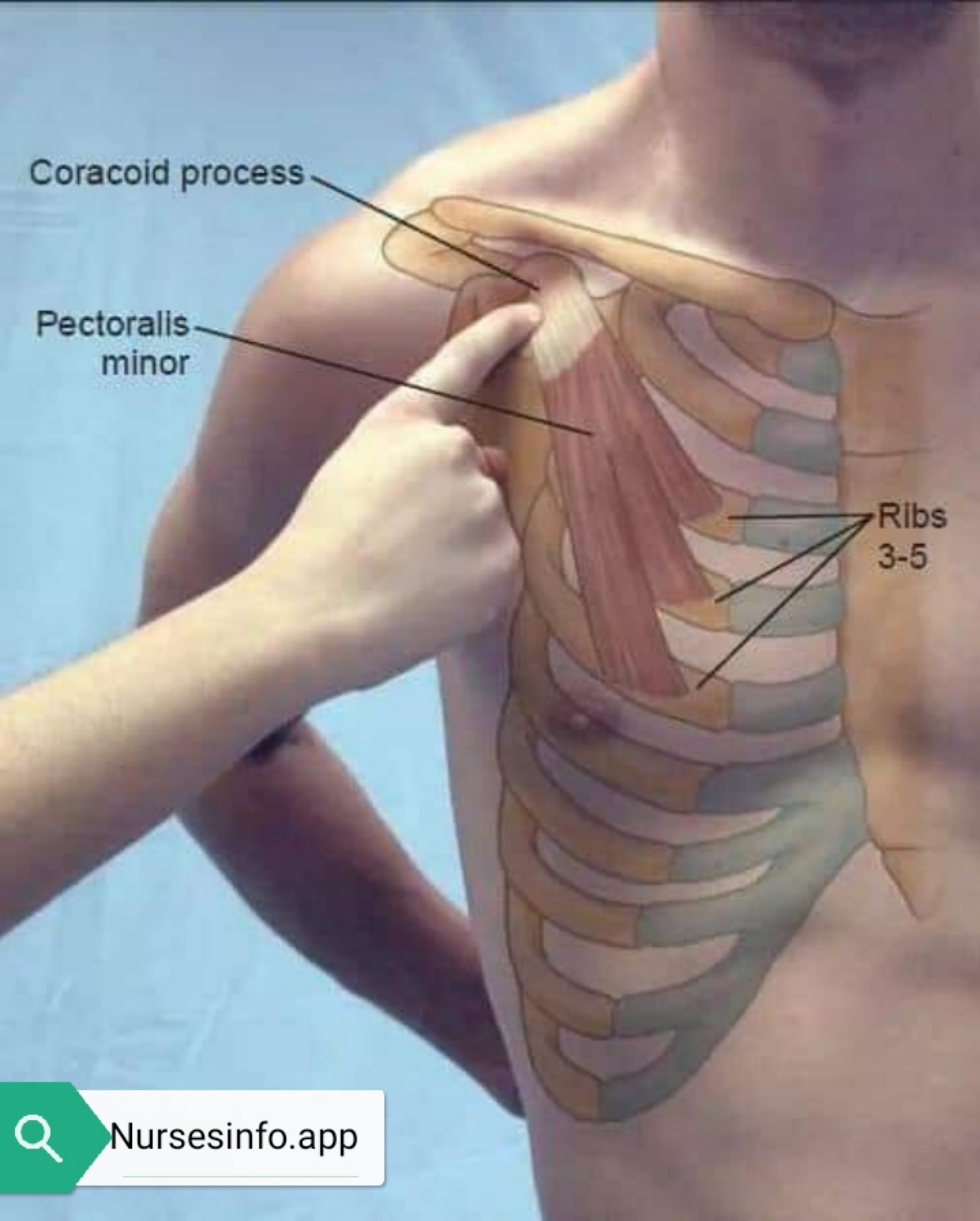
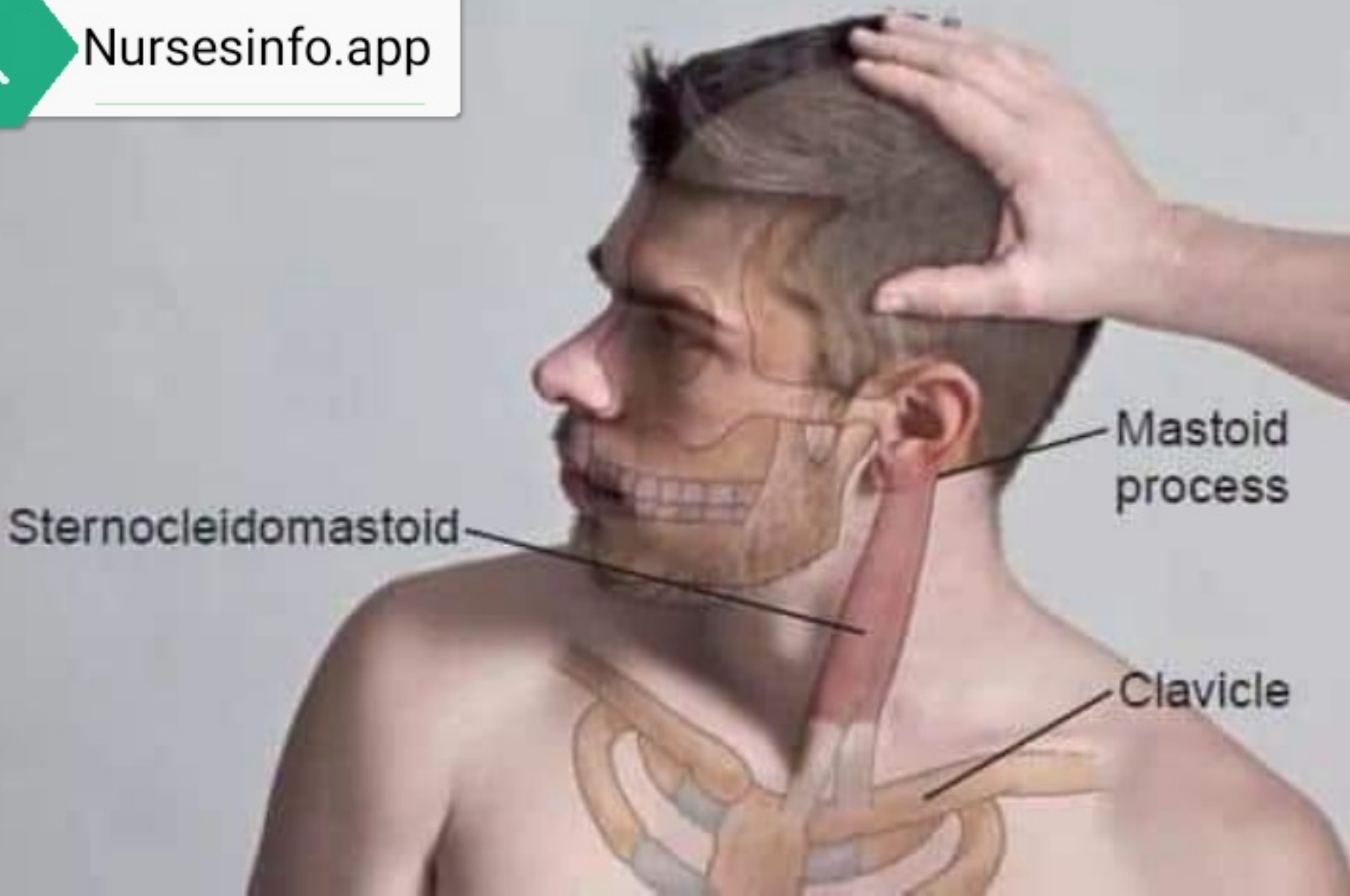

Coracoid process

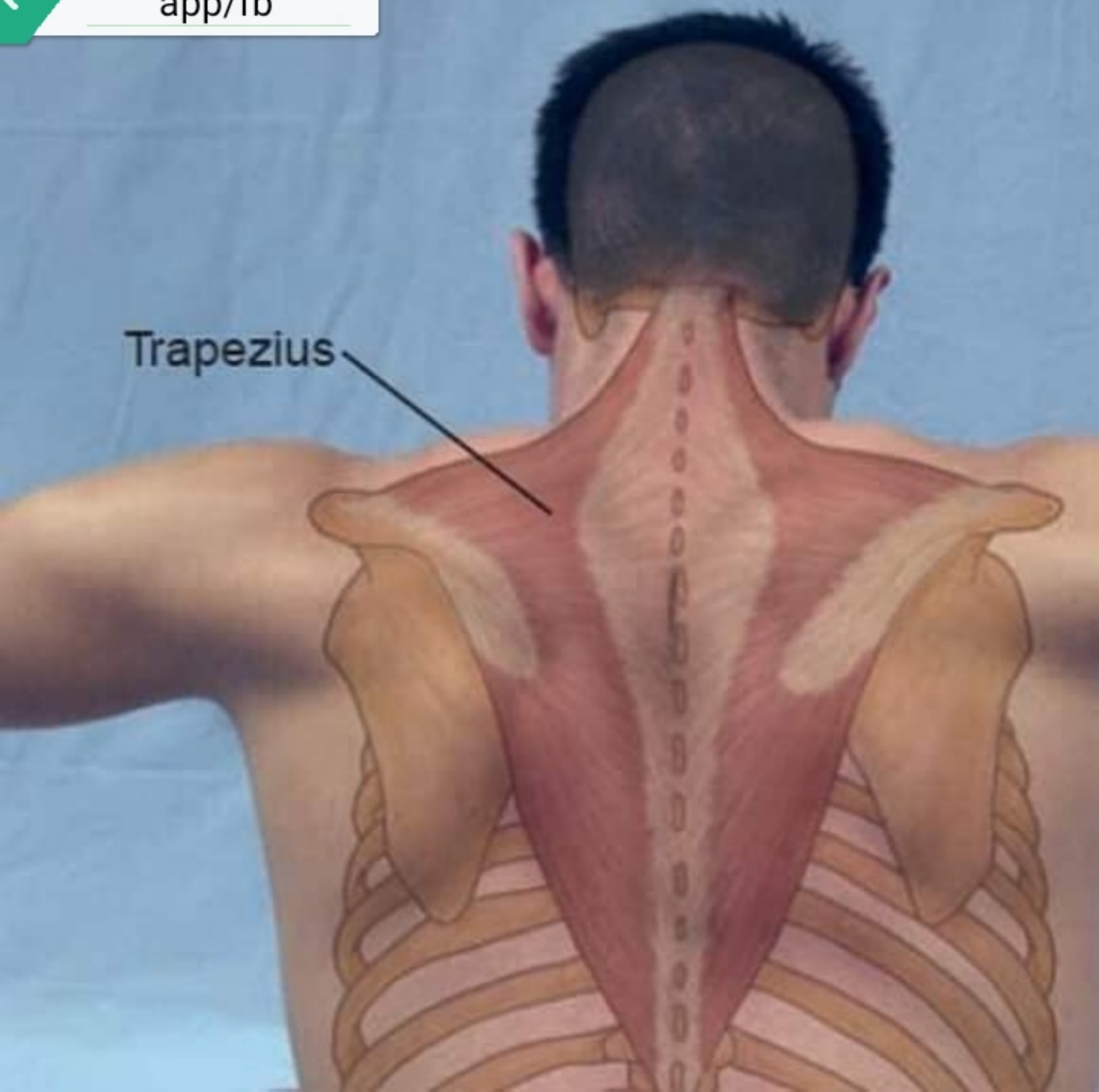Pectoralis minor

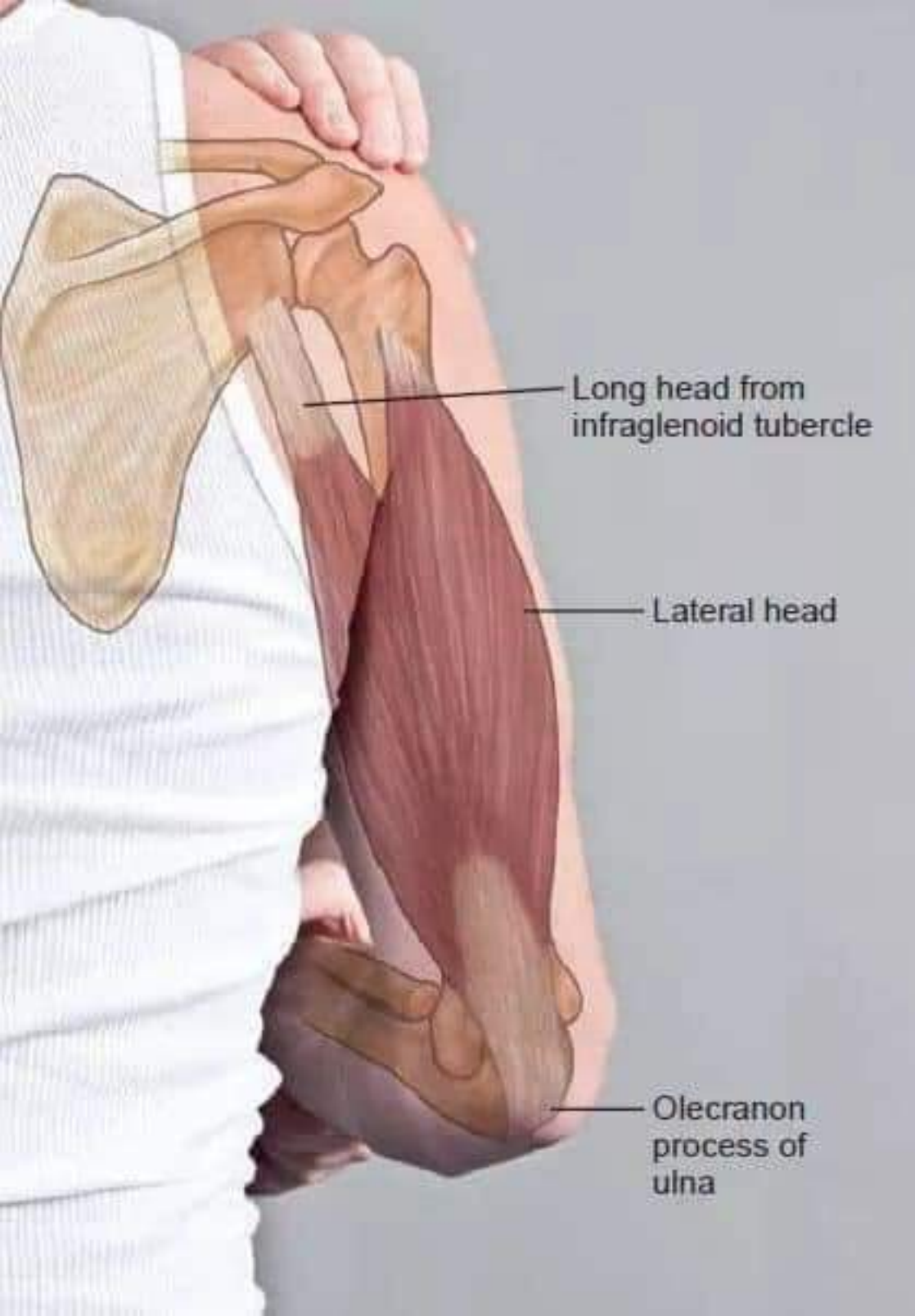
Ribs 3-5





Trapezius

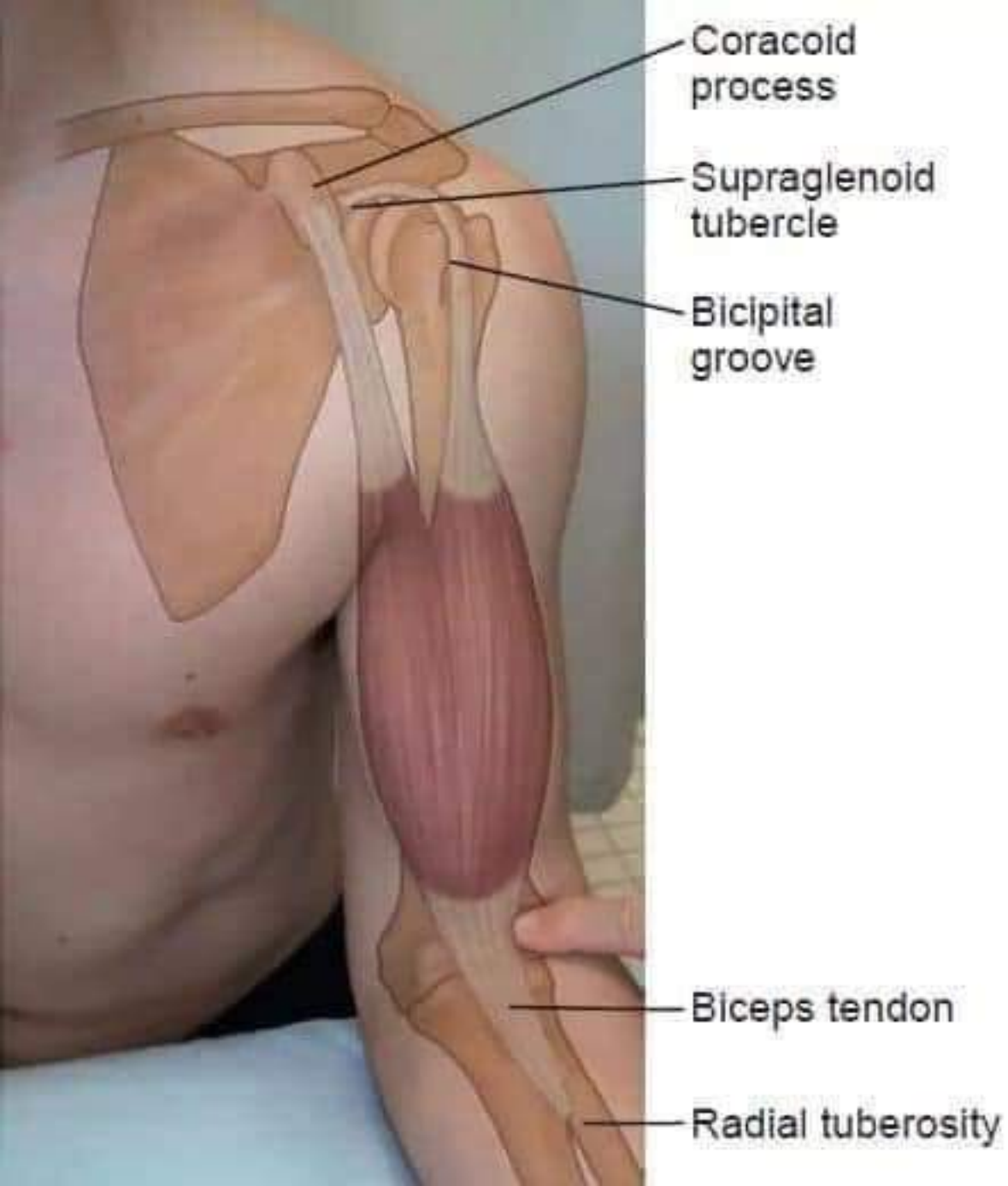




Long head from
infraglenoid tubercle

Lateral head

Olecranon
process of
ulna



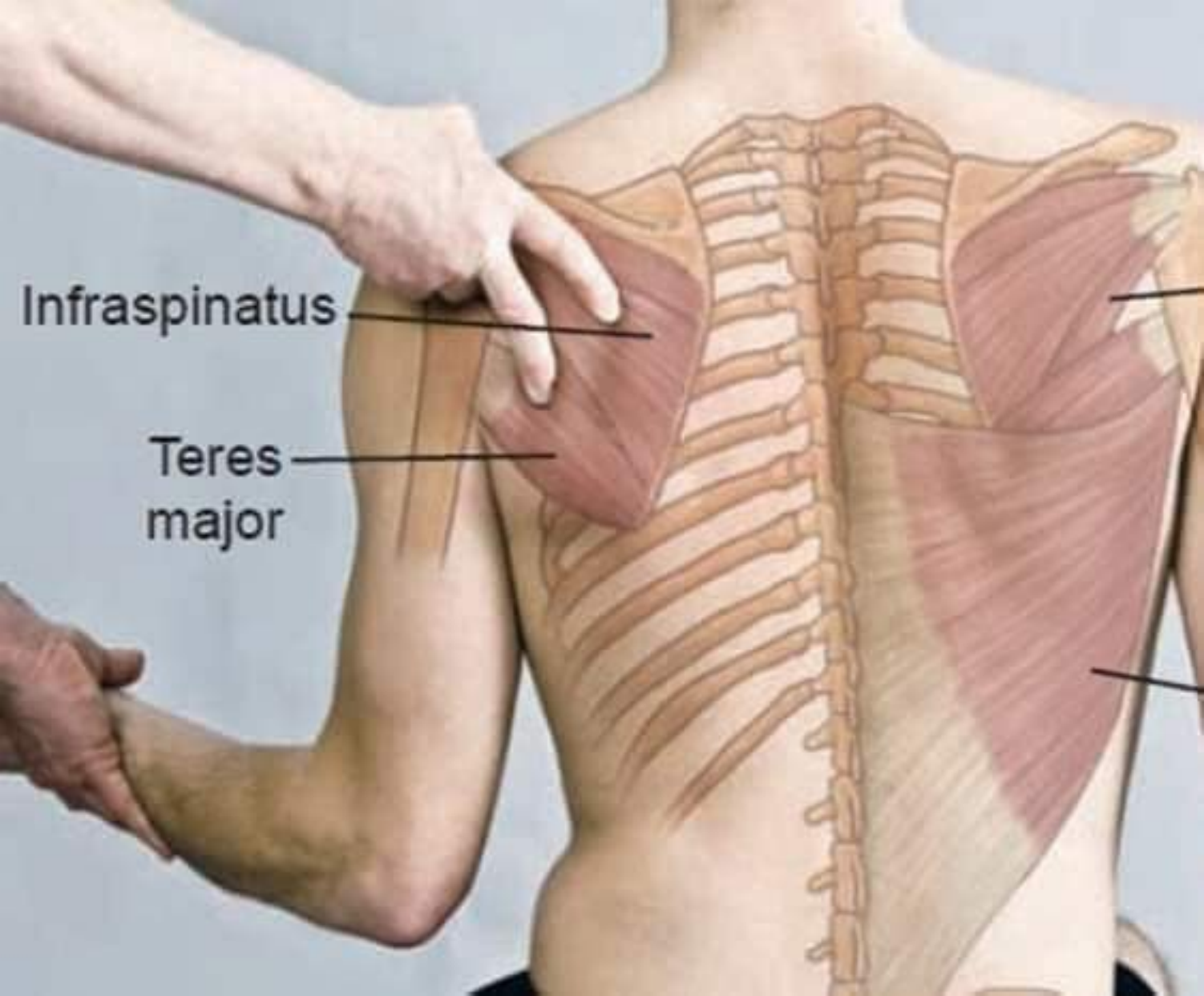
Coracoid process

Supraglenoid tubercle

Bicipital groove

Biceps tendon

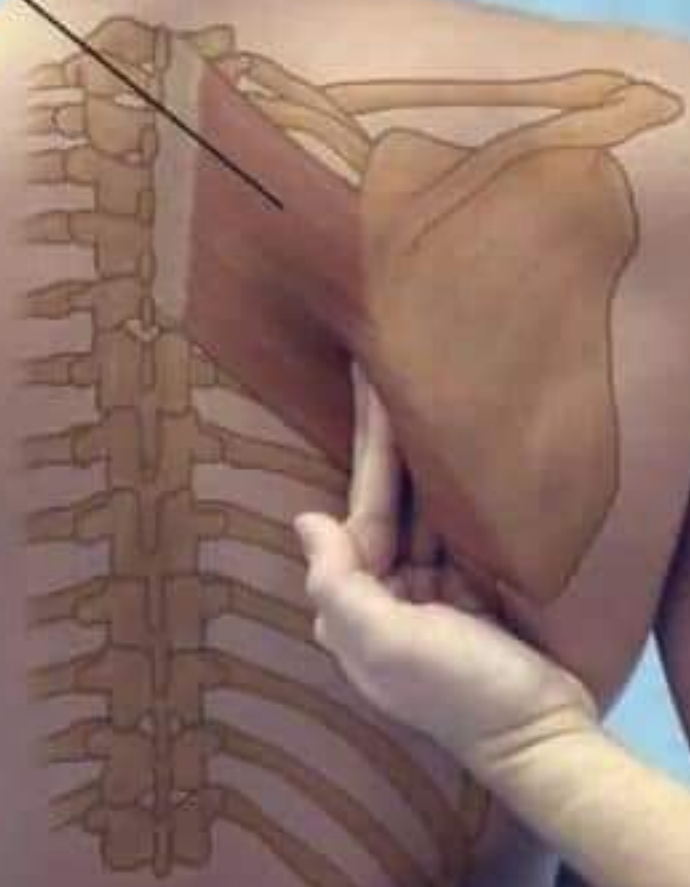Radial tuberosity

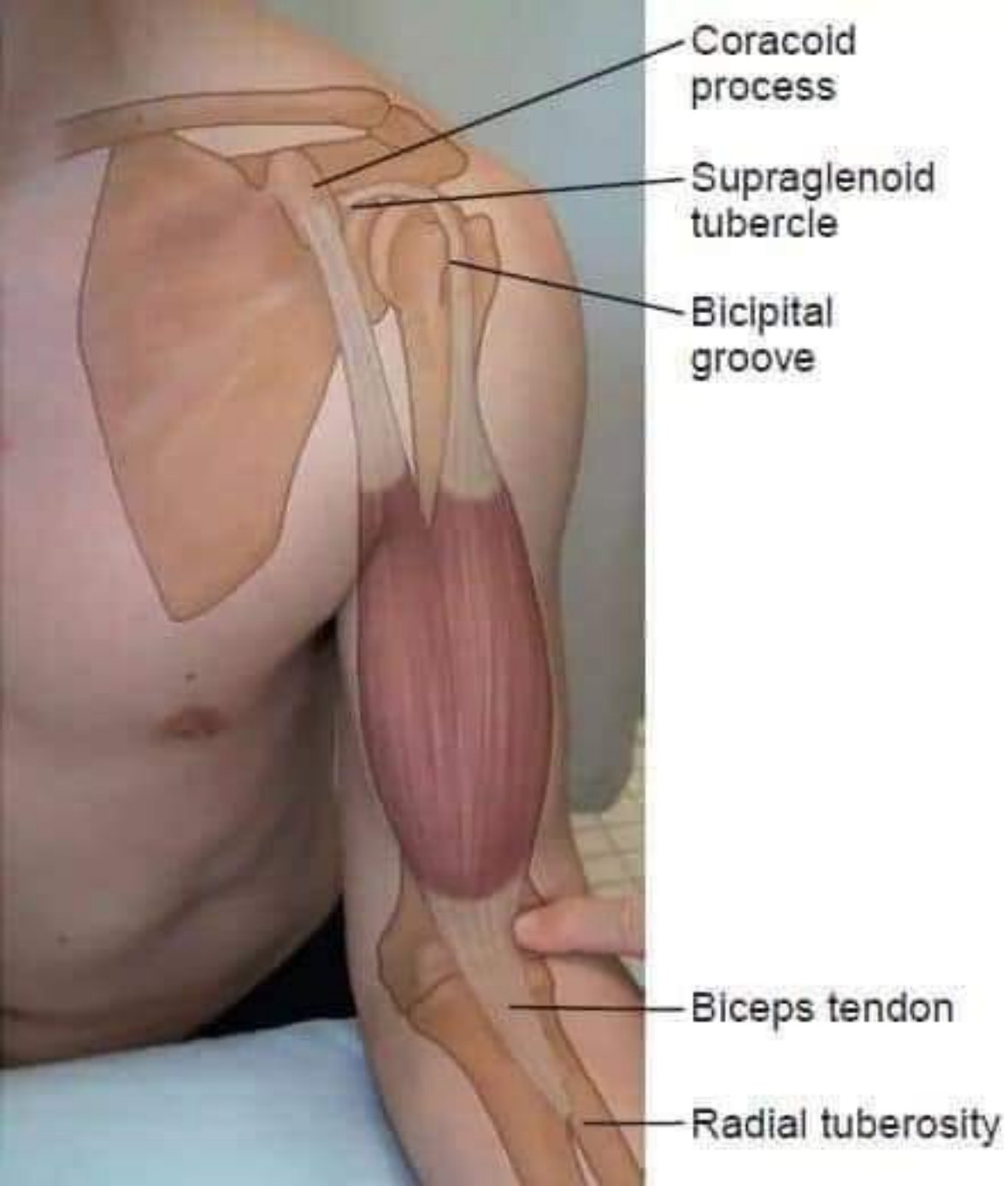


Infraspinatus

Teres
major

Rhomboids





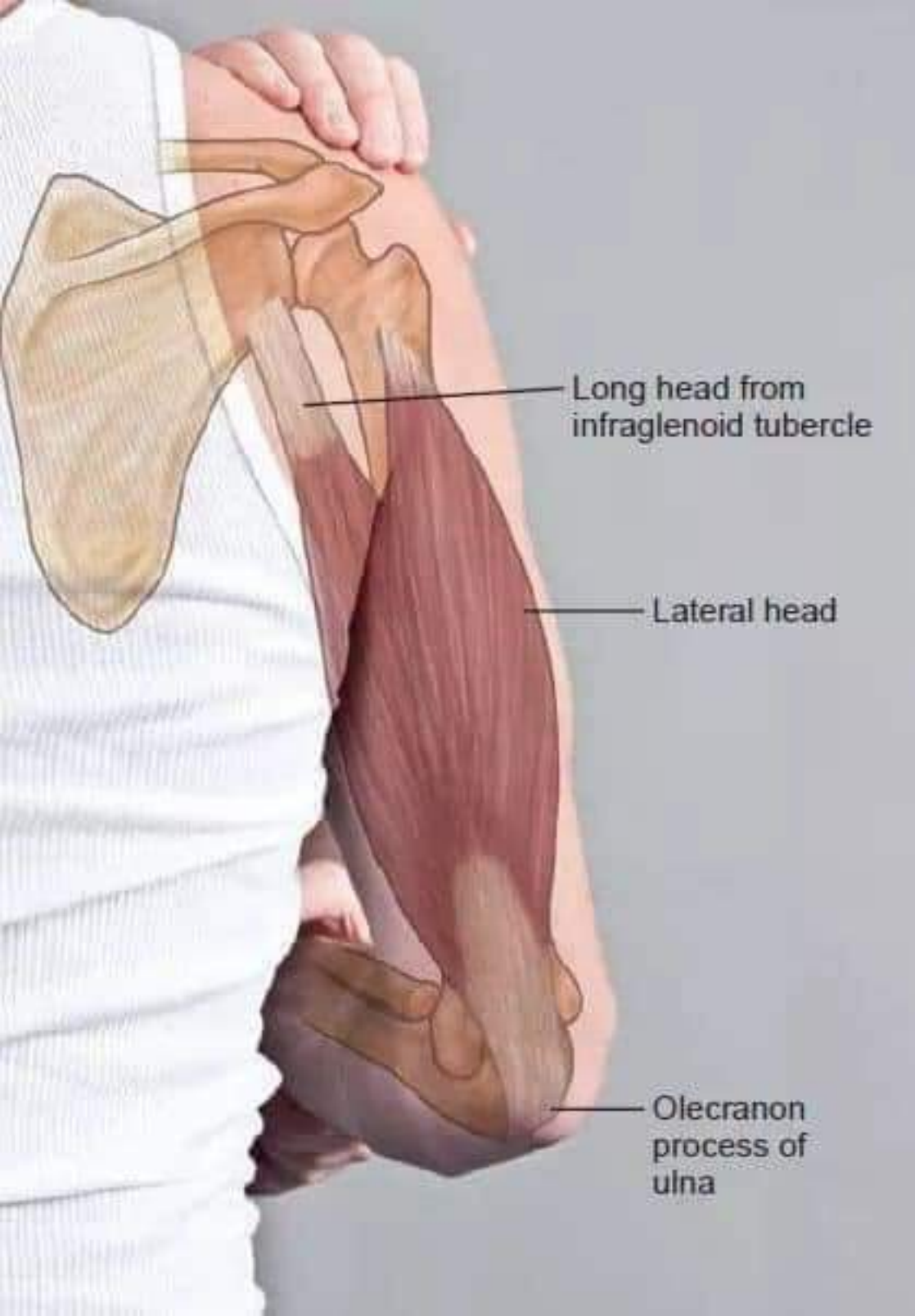
Coracoid process

Supraglenoid tubercle

Bicipital groove

Biceps tendon

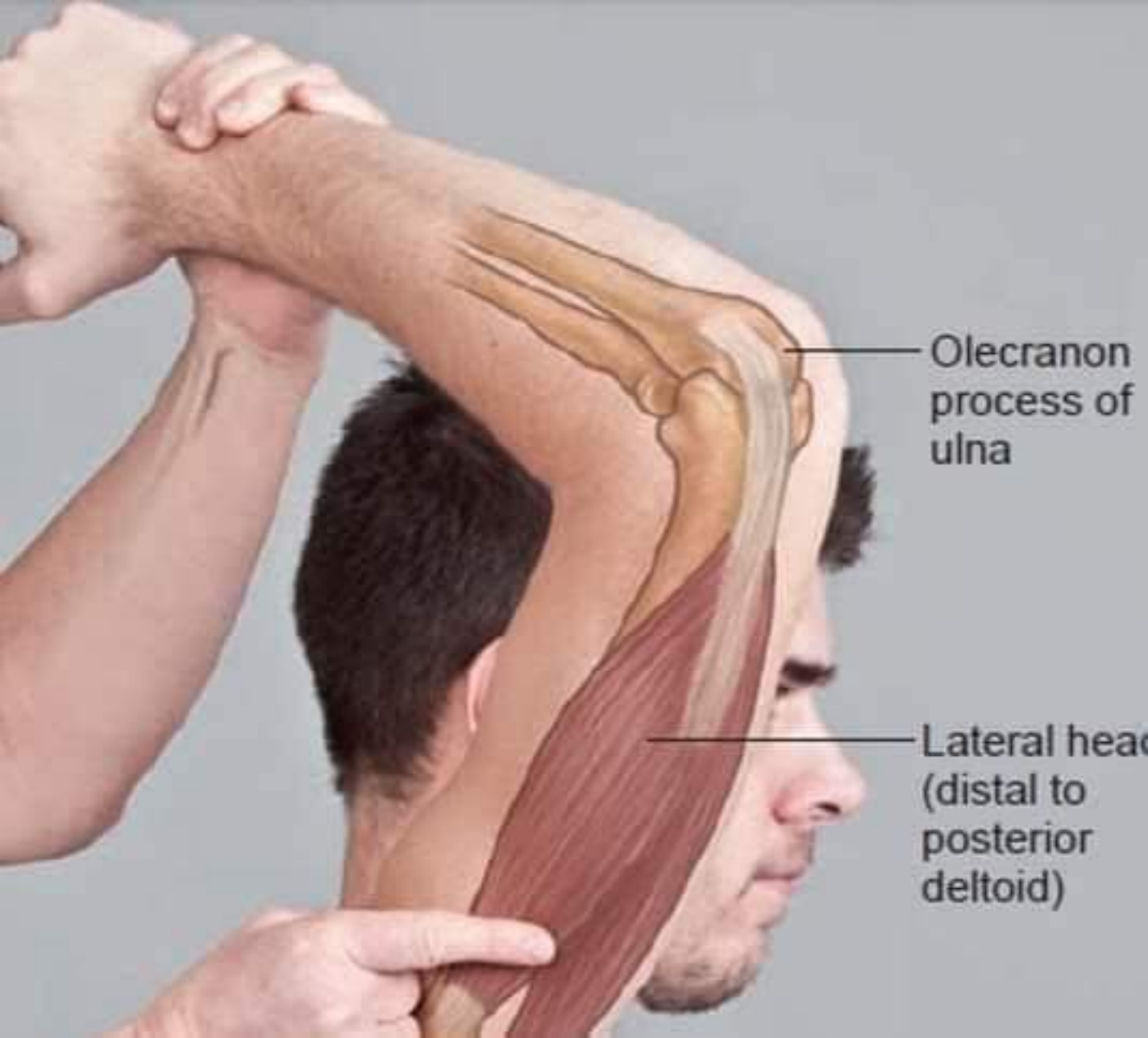Radial tuberosity



Long head from
infraglenoid tubercle

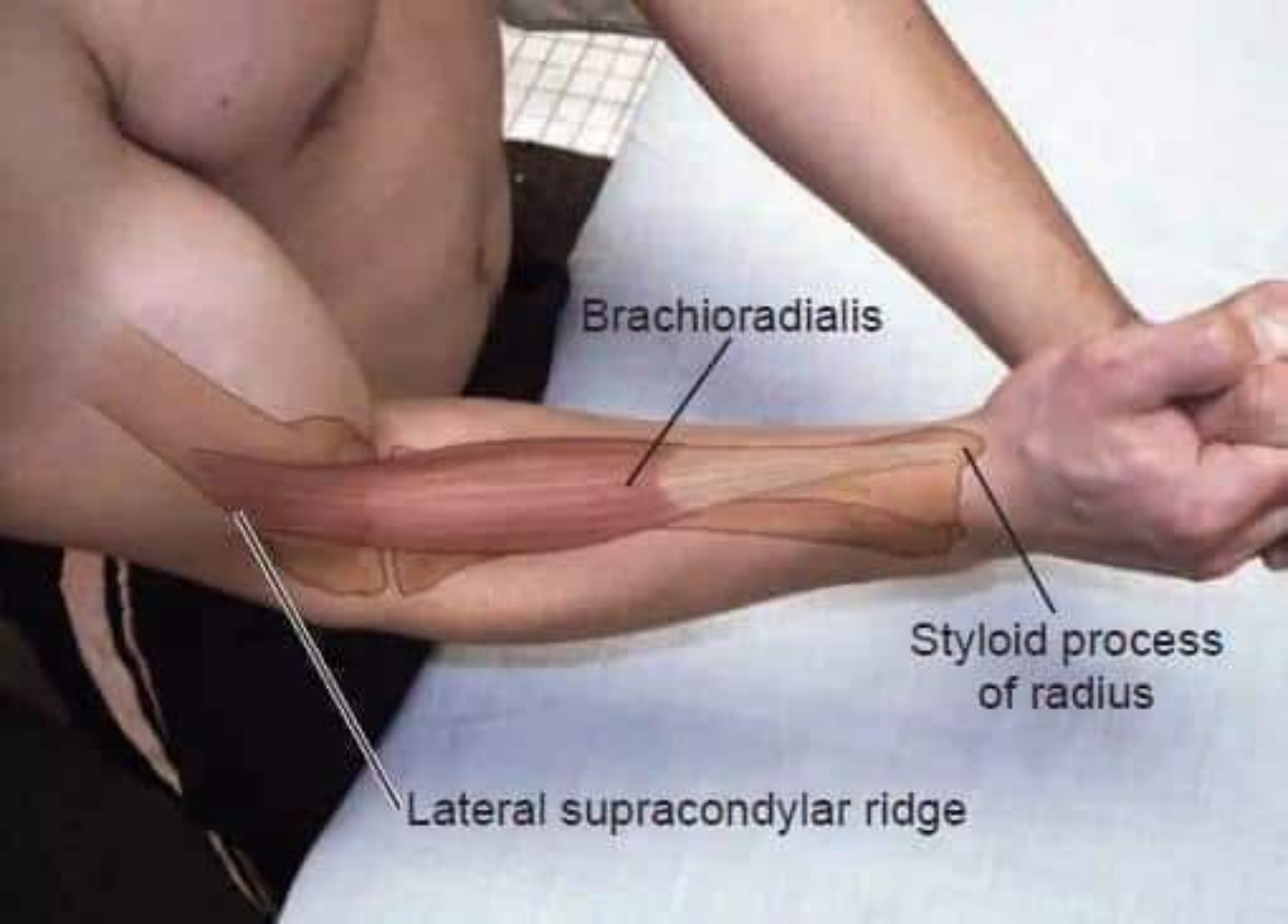
Lateral head

Olecranon
process of
ulna



Olecranon
process of
ulna

Lateral head
(distal to
posterior
deltoid)

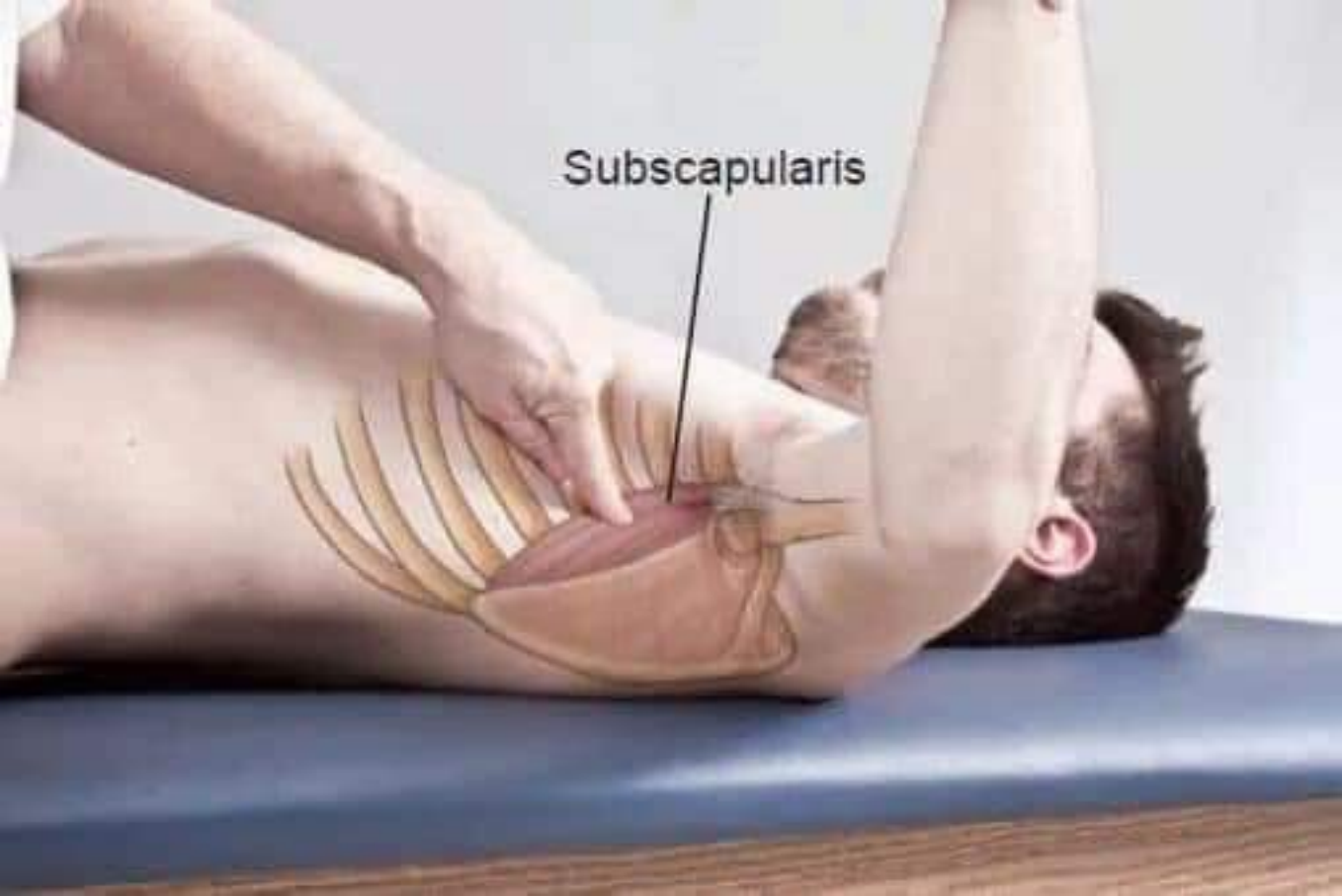

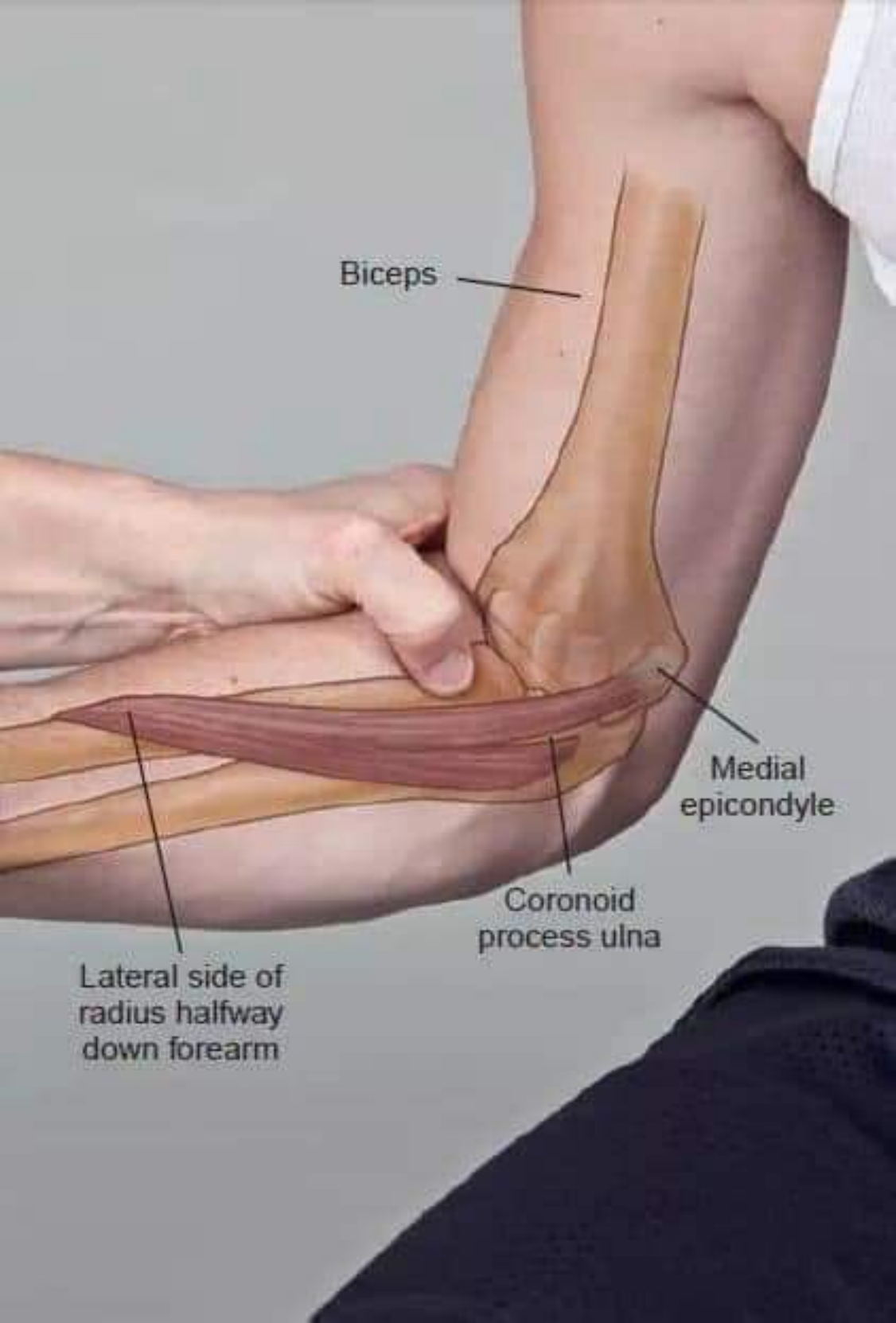Brachioradialis

Styloid process
of radius

Lateral supracondylar ridge

Subscapularis



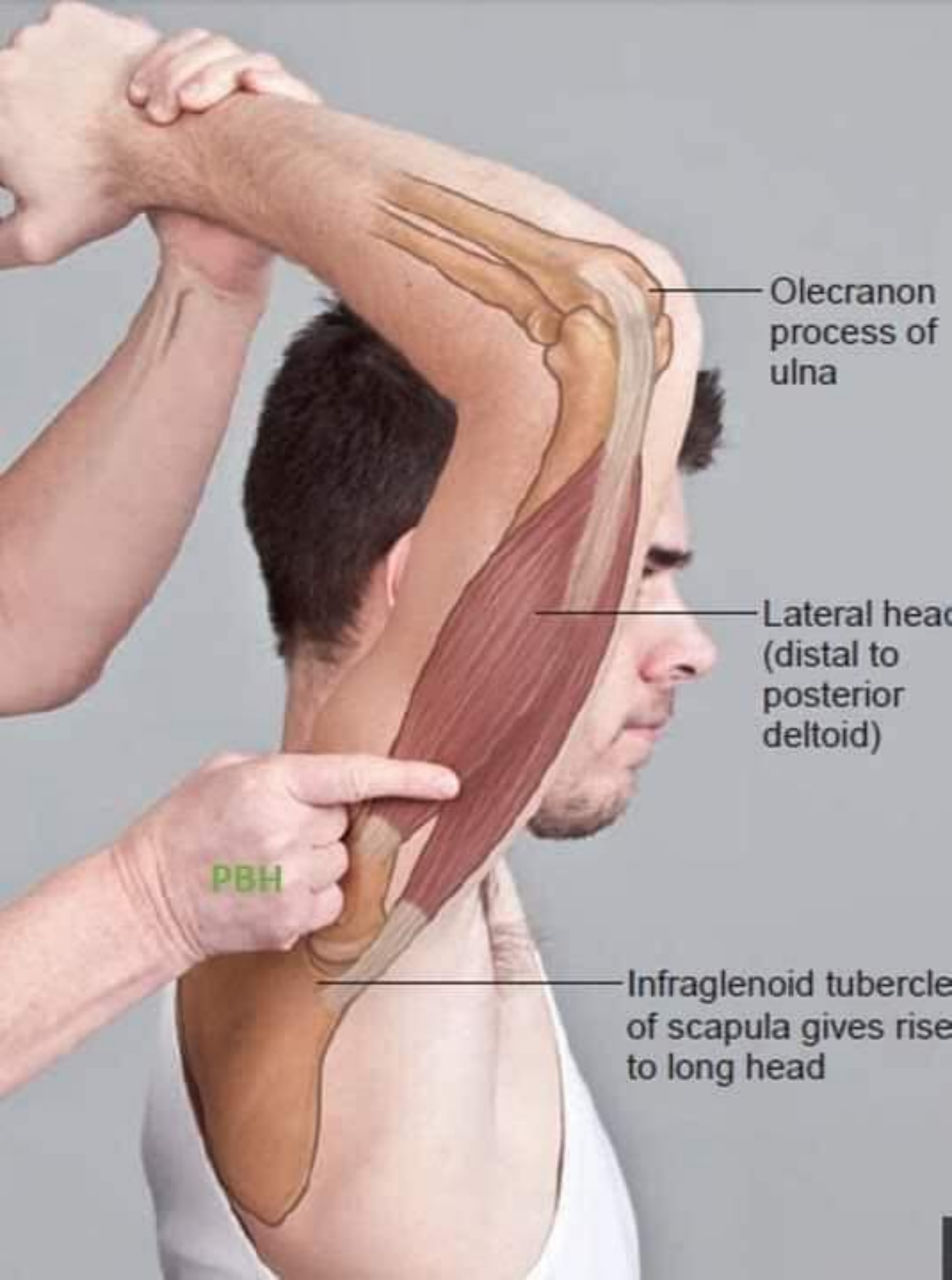

Biceps

Medial epicondyle

Coronoid process ulna

Lateral side of radius halfway down forearm

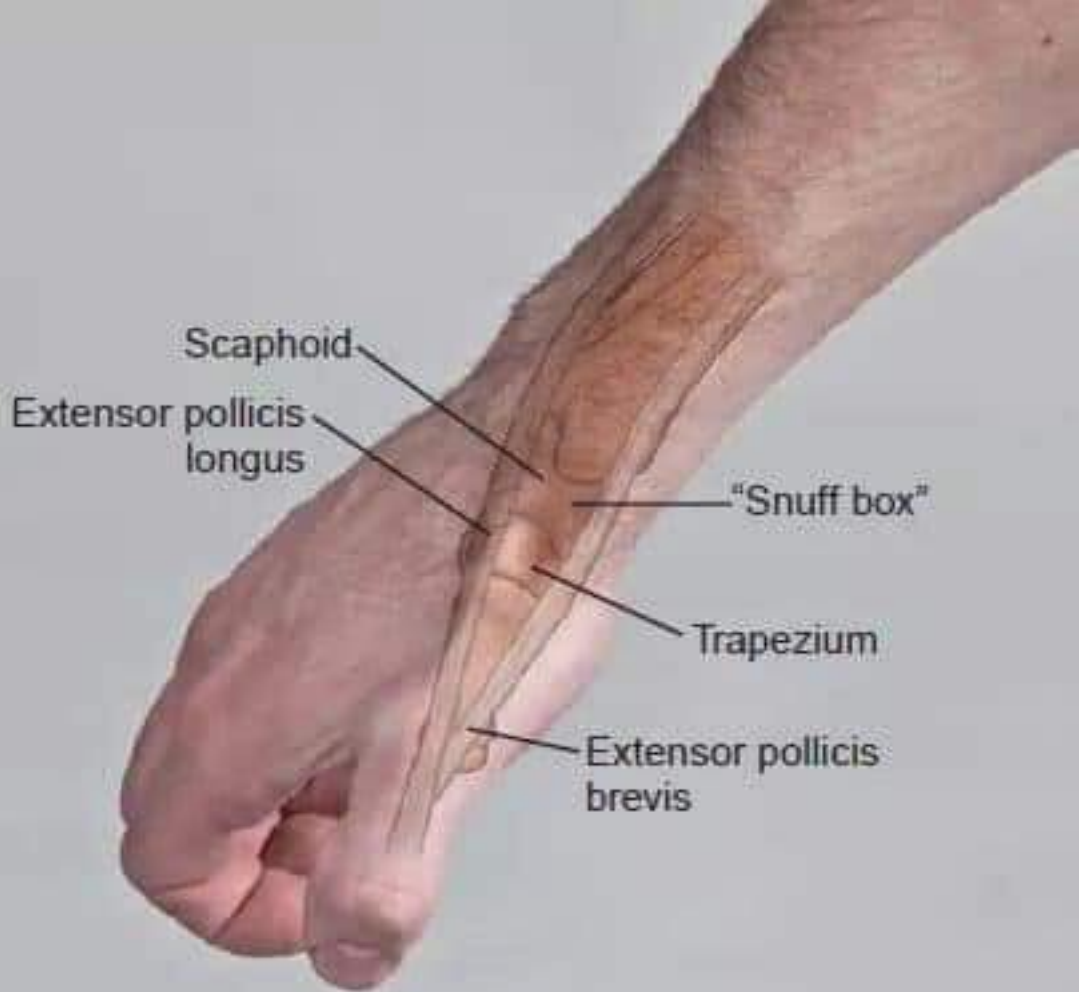

Olecranon process of ulna

Lateral head (distal to posterior deltoid)

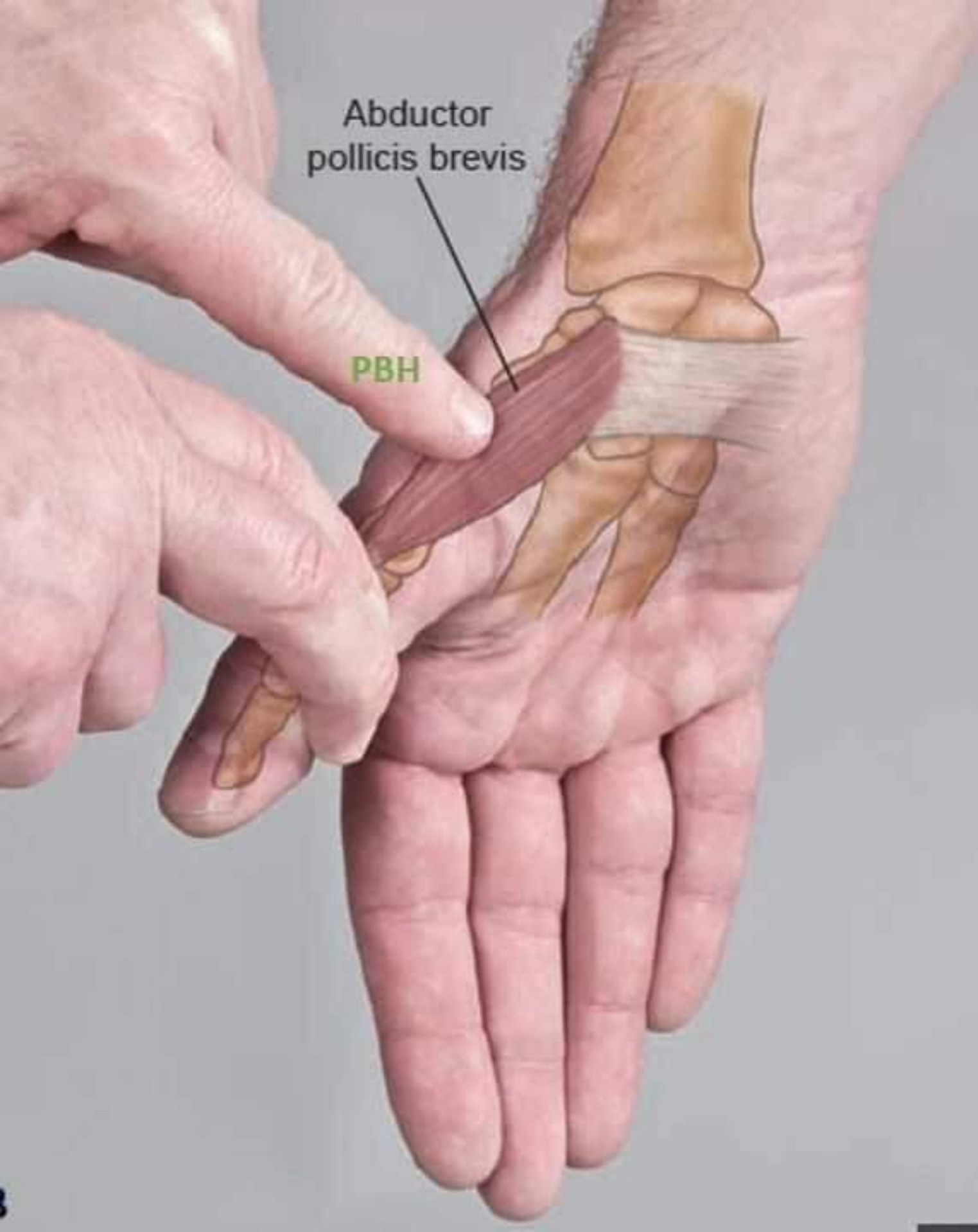PBH

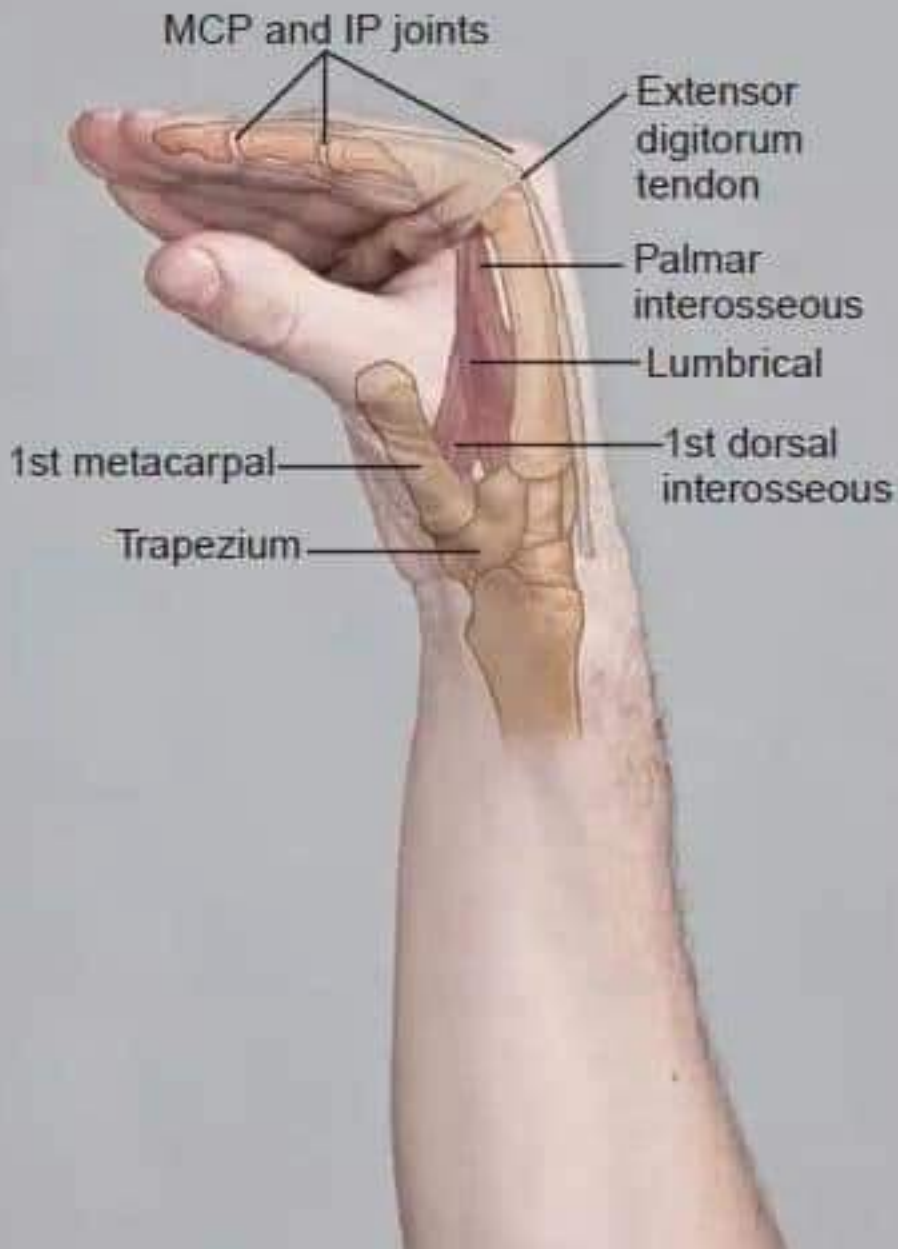Infraglenoid tubercle of scapula gives rise to long head

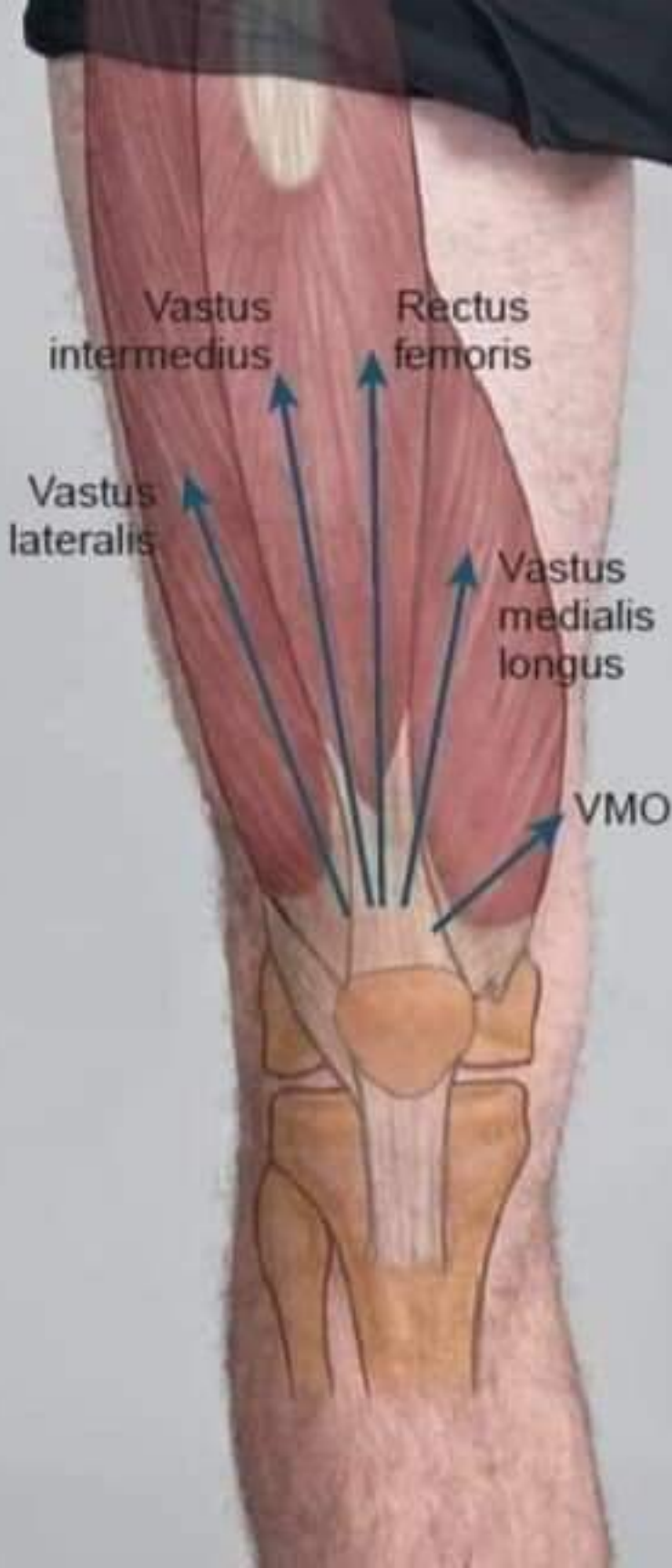


Abductor
pollicis brevis

PBH







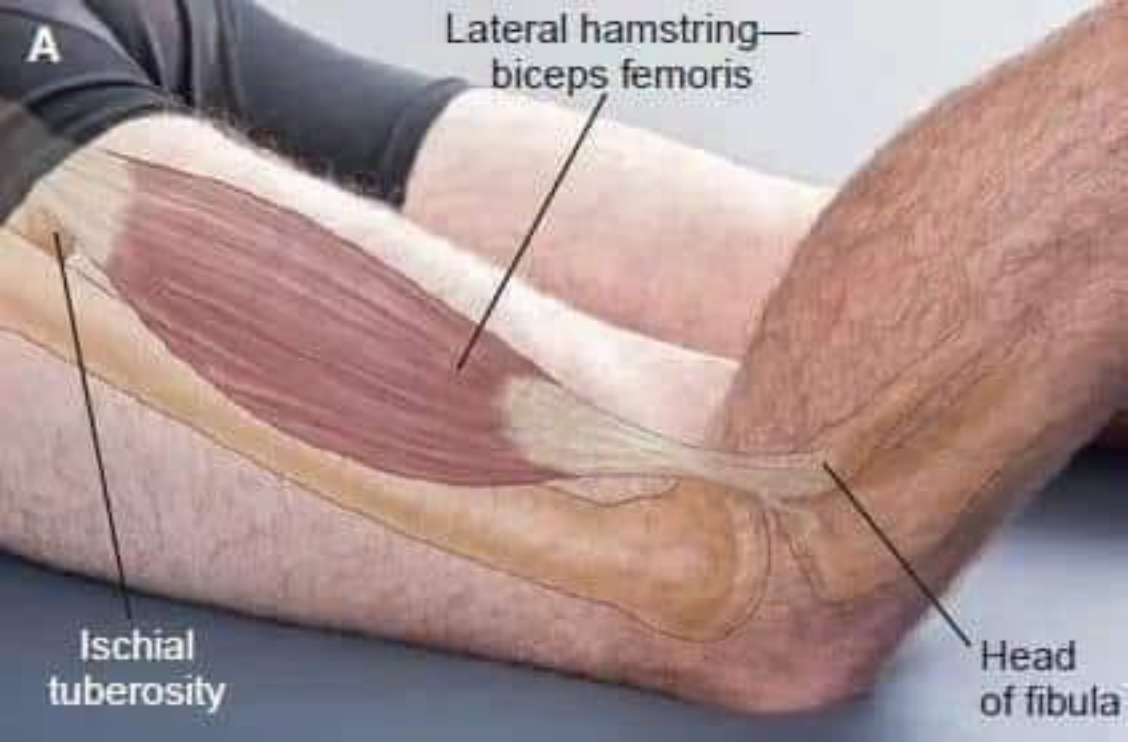
Vastus intermedius

Rectus femoris

Vastus lateralis

Vastus medialis longus

VMO



A

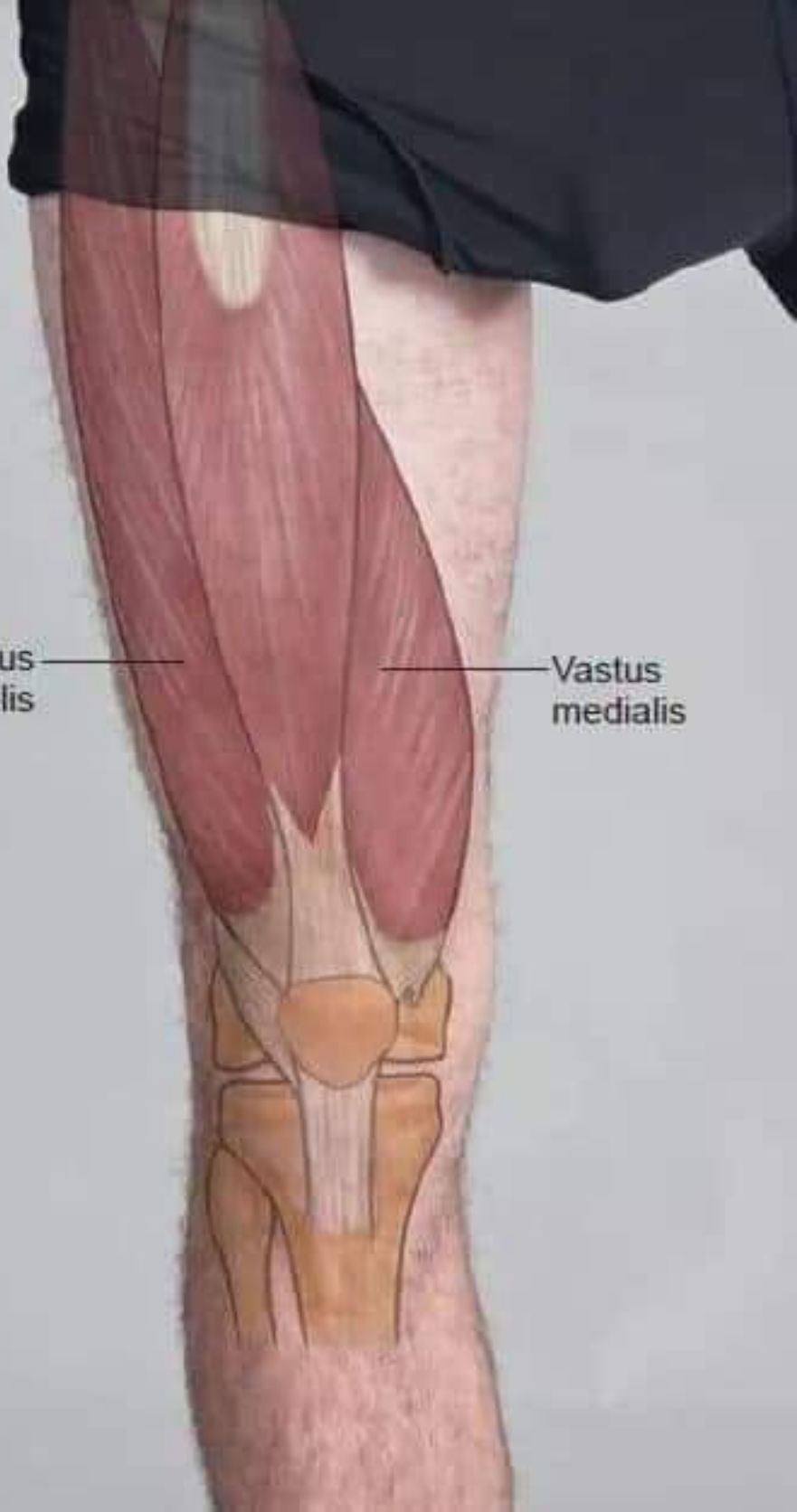
Lateral hamstring—
biceps femoris

Ischial
tuberosity

Head
of fibula

Vastus
lateralis

Vastus
medialis

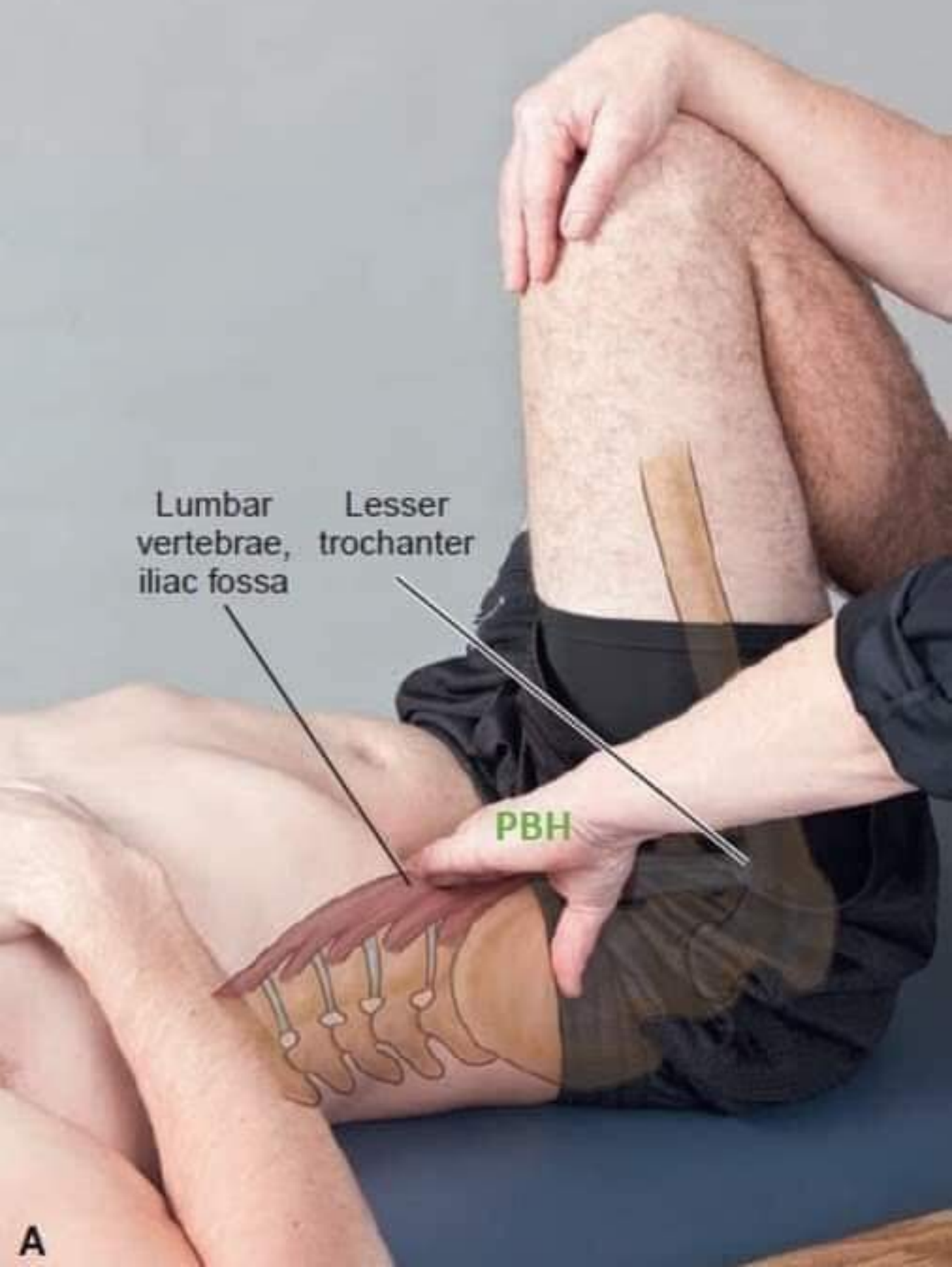


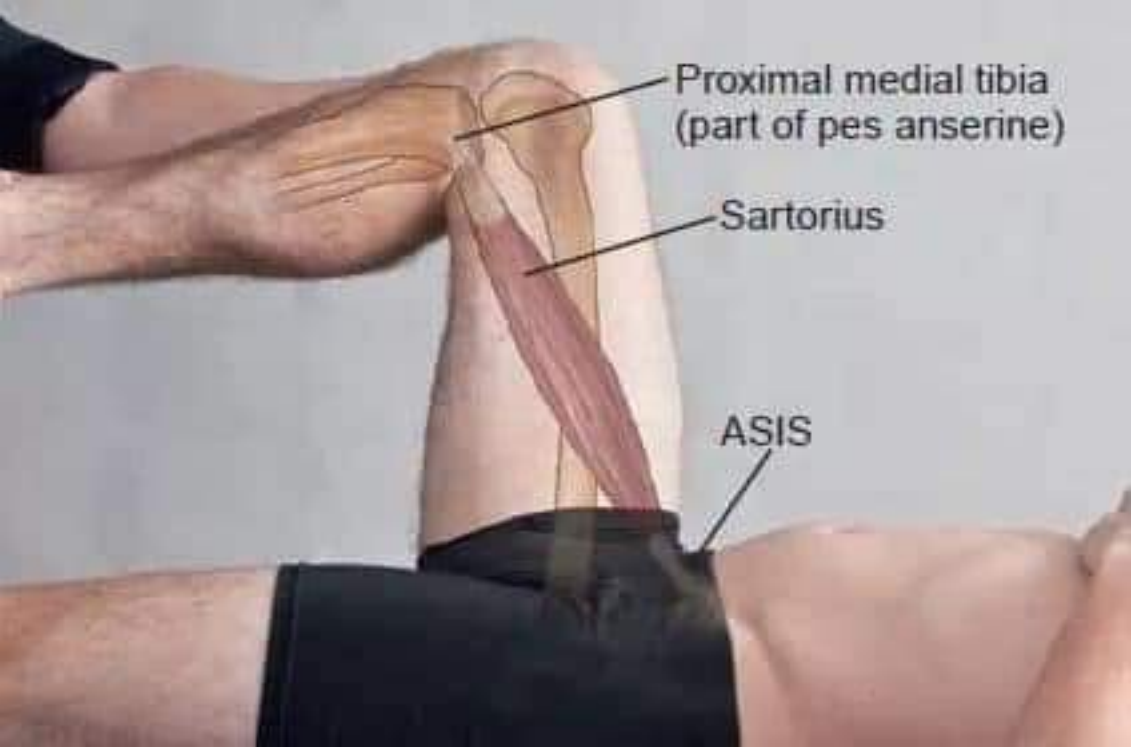Lumbar
vertebrae,
iliac fossa

Lesser
trochanter

PBH

A





Proximal medial tibia
(part of pes anserine)

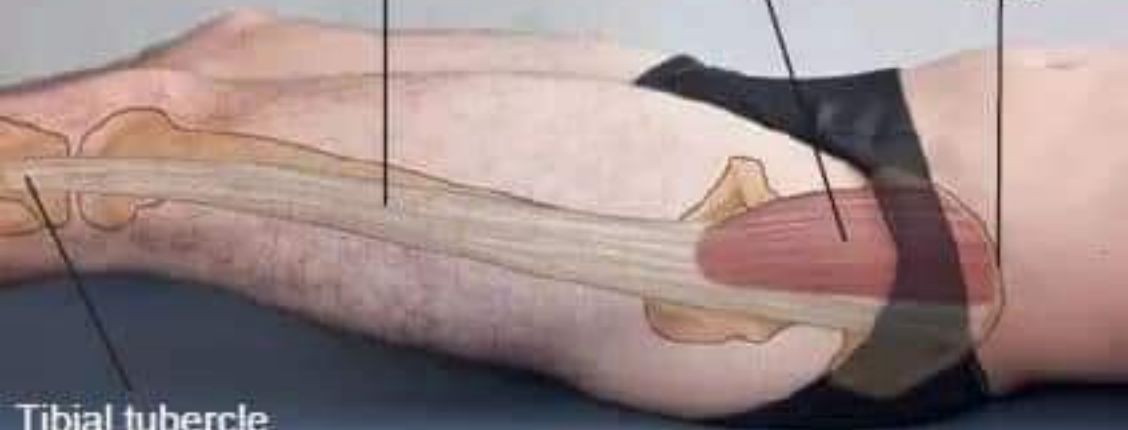Sartorius

ASIS

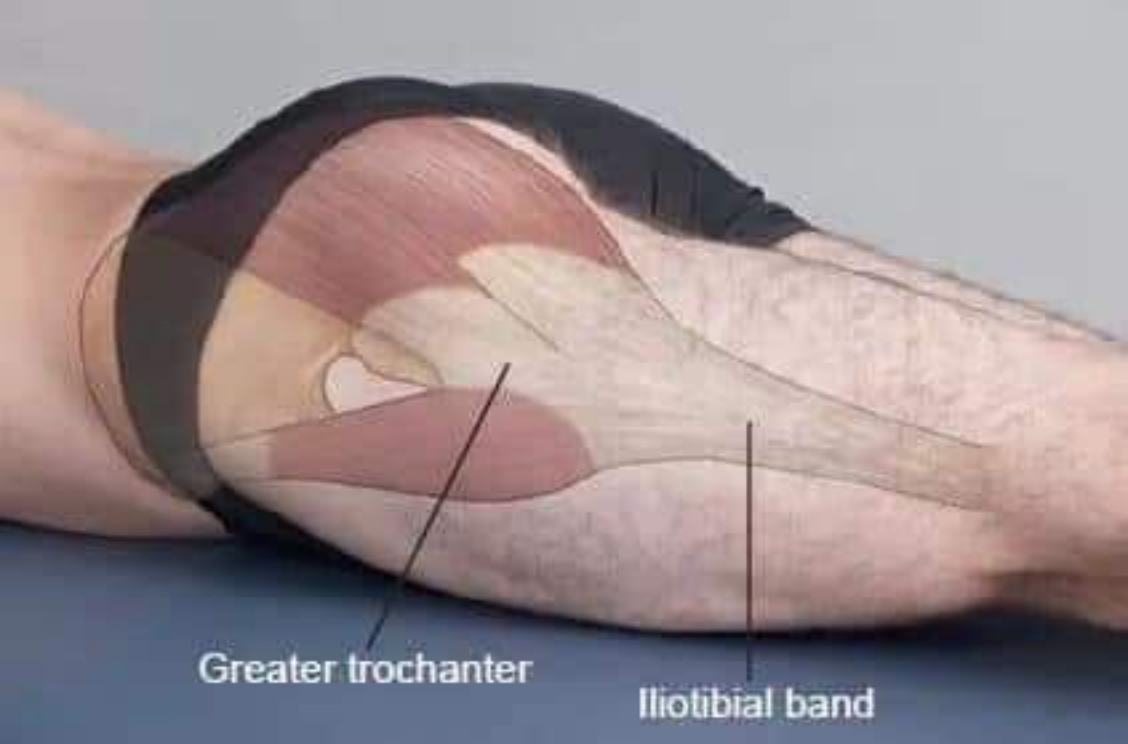
Iliotibial tract (ITT)
or band (ITB)

Tensor
fascia lata

Iliac
crest

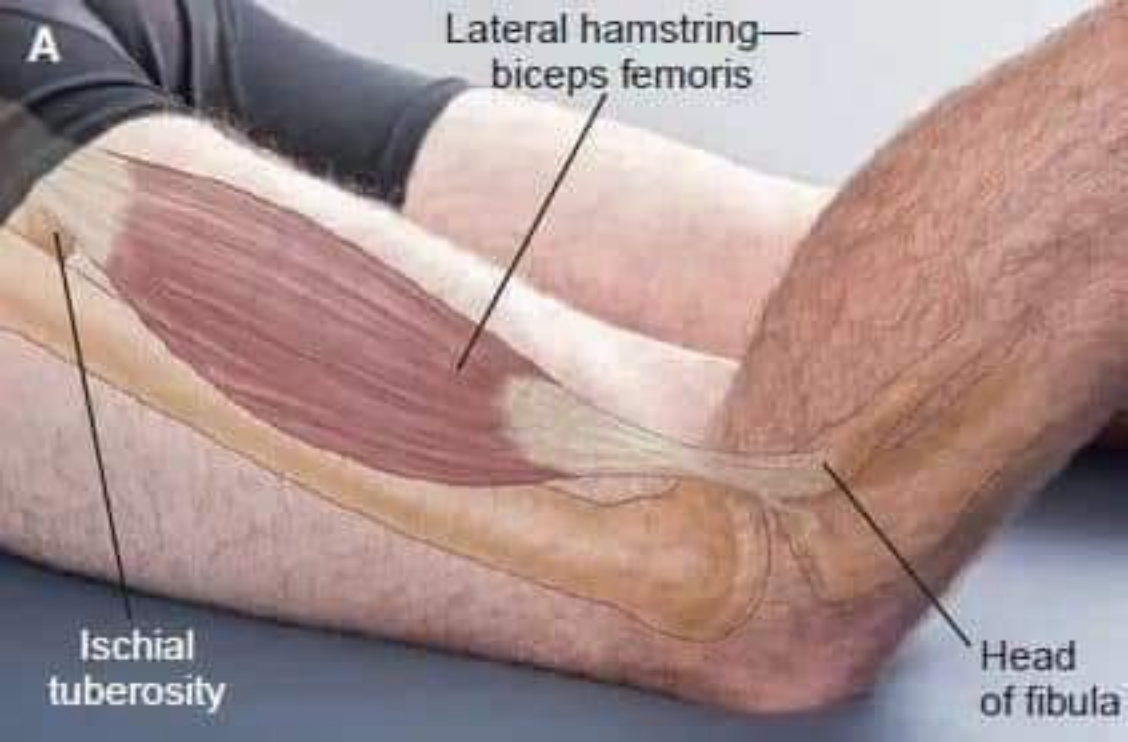


Tibial tubercle



Greater trochanter

Iliotibial band



A

Lateral hamstring—
biceps femoris

Ischial
tuberosity

Head
of fibula

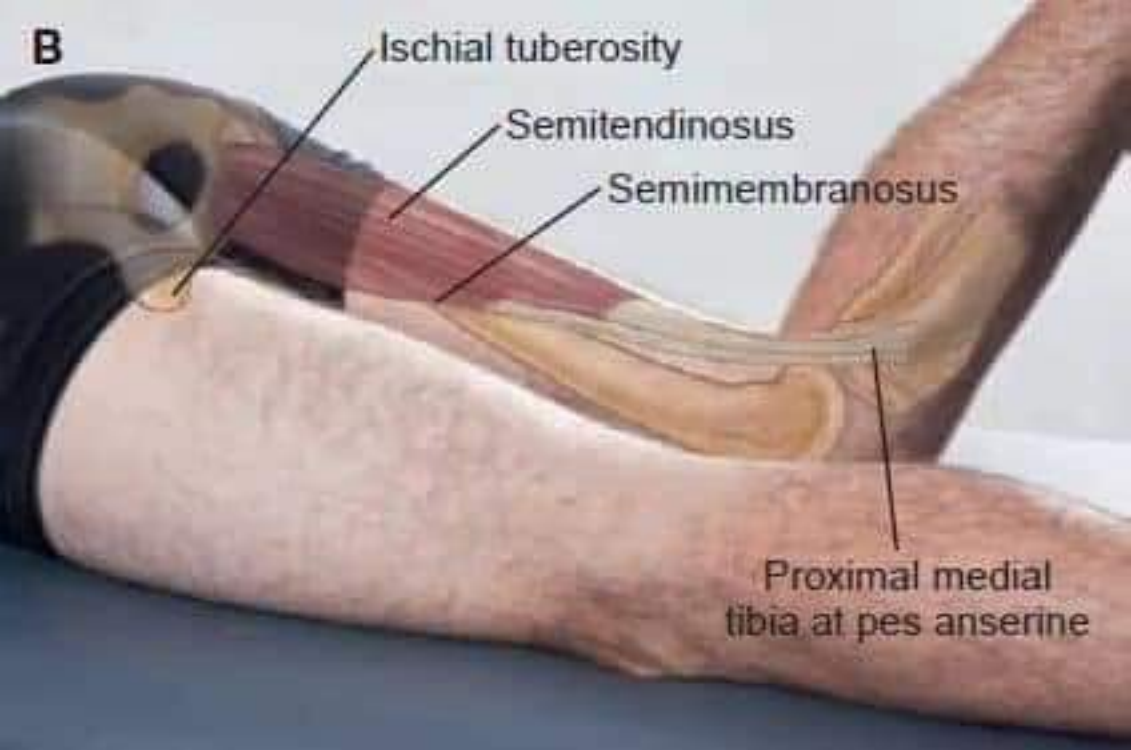
B

Ischial tuberosity

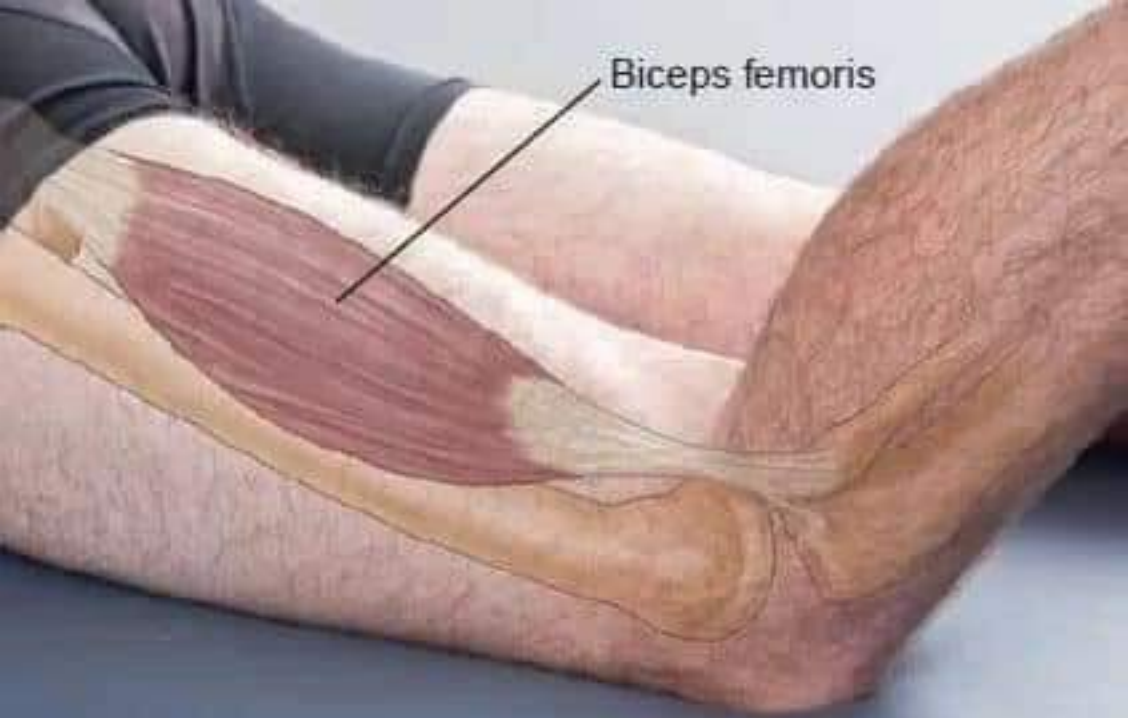
Semitendinosus

Semimembranosus

Proximal medial
tibia at pes anserine

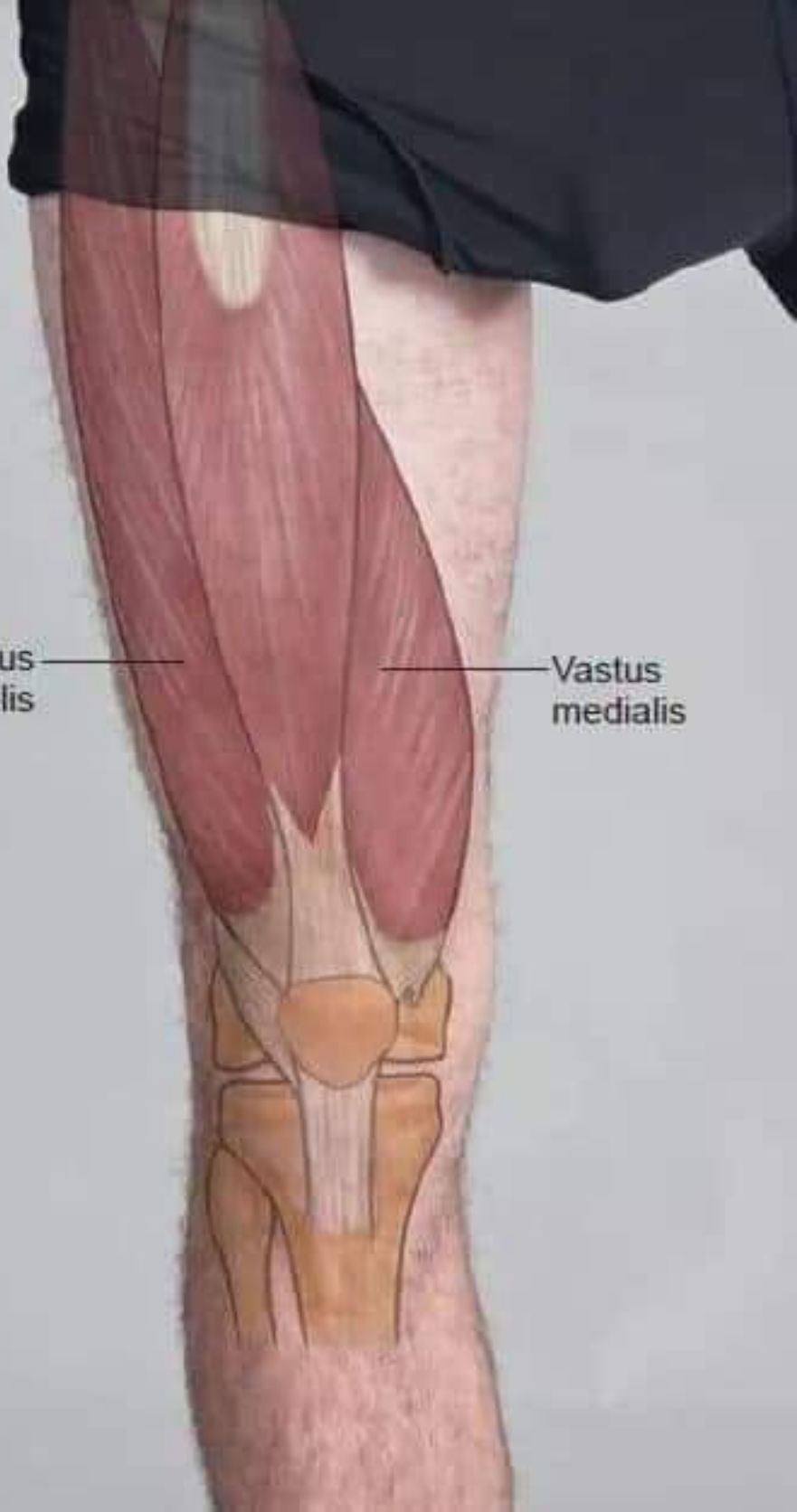


Biceps femoris



Vastus
lateralis

Vastus
medialis



Rectus femoris

AIIS

