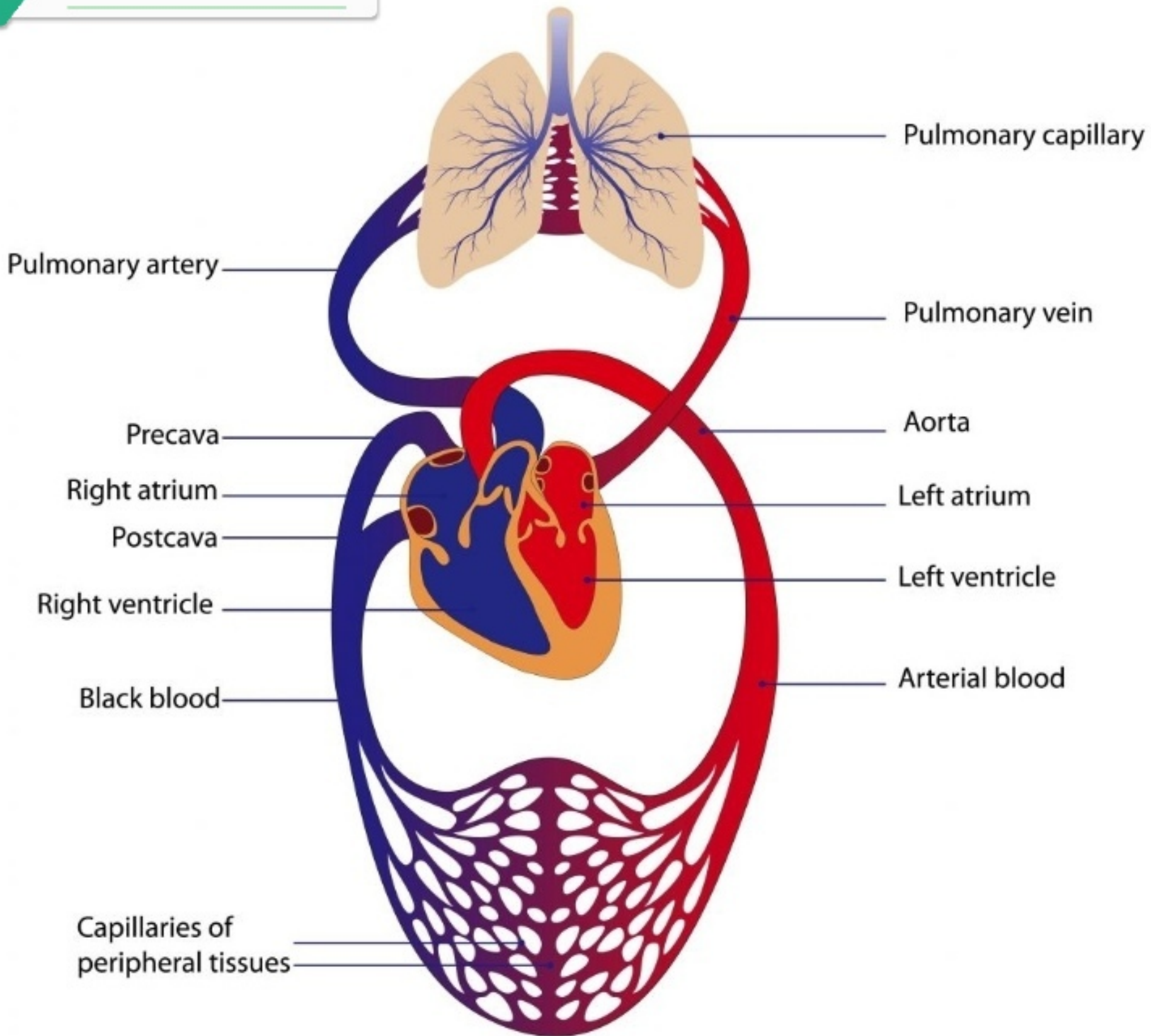
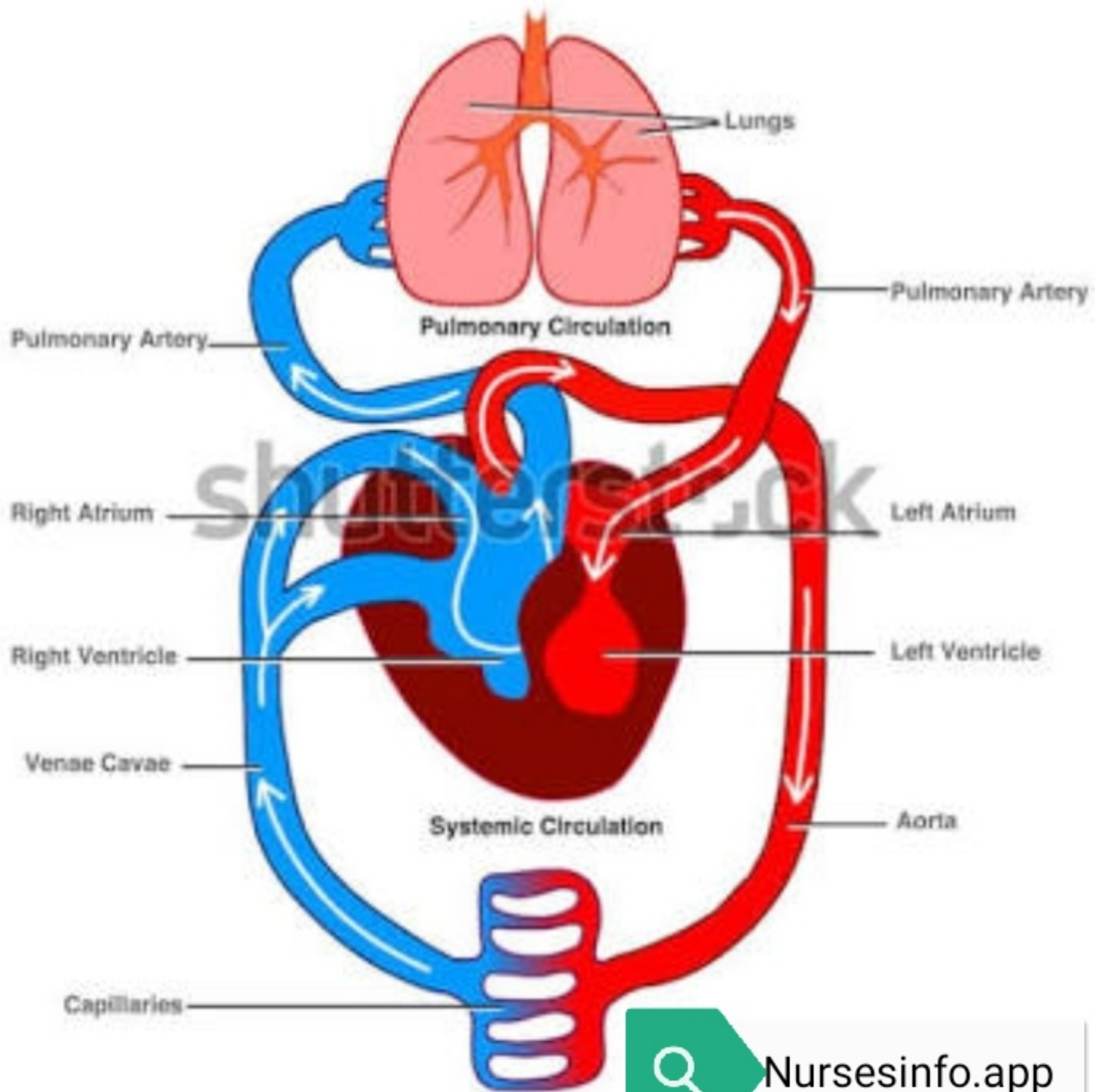
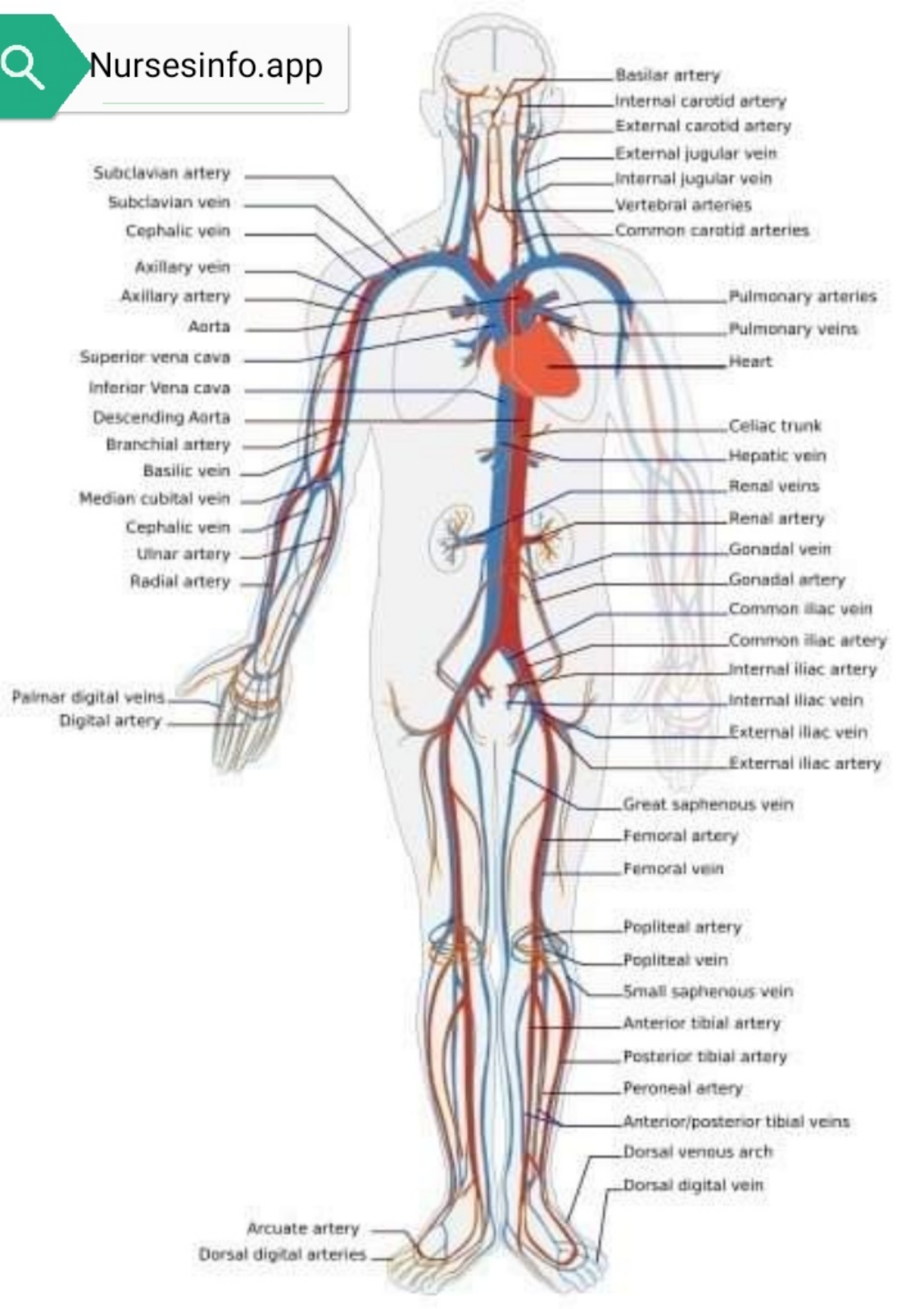


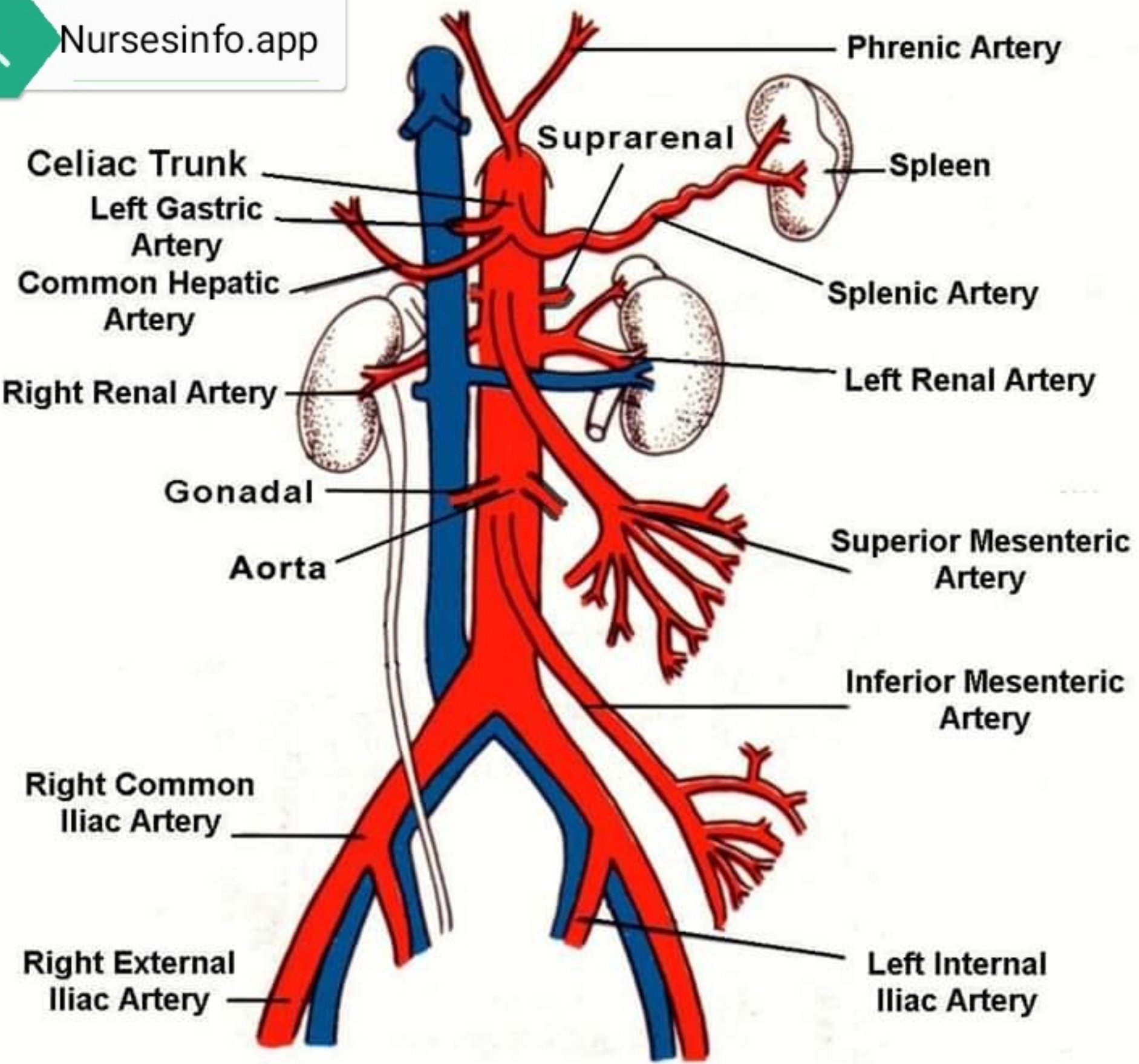
Circulation



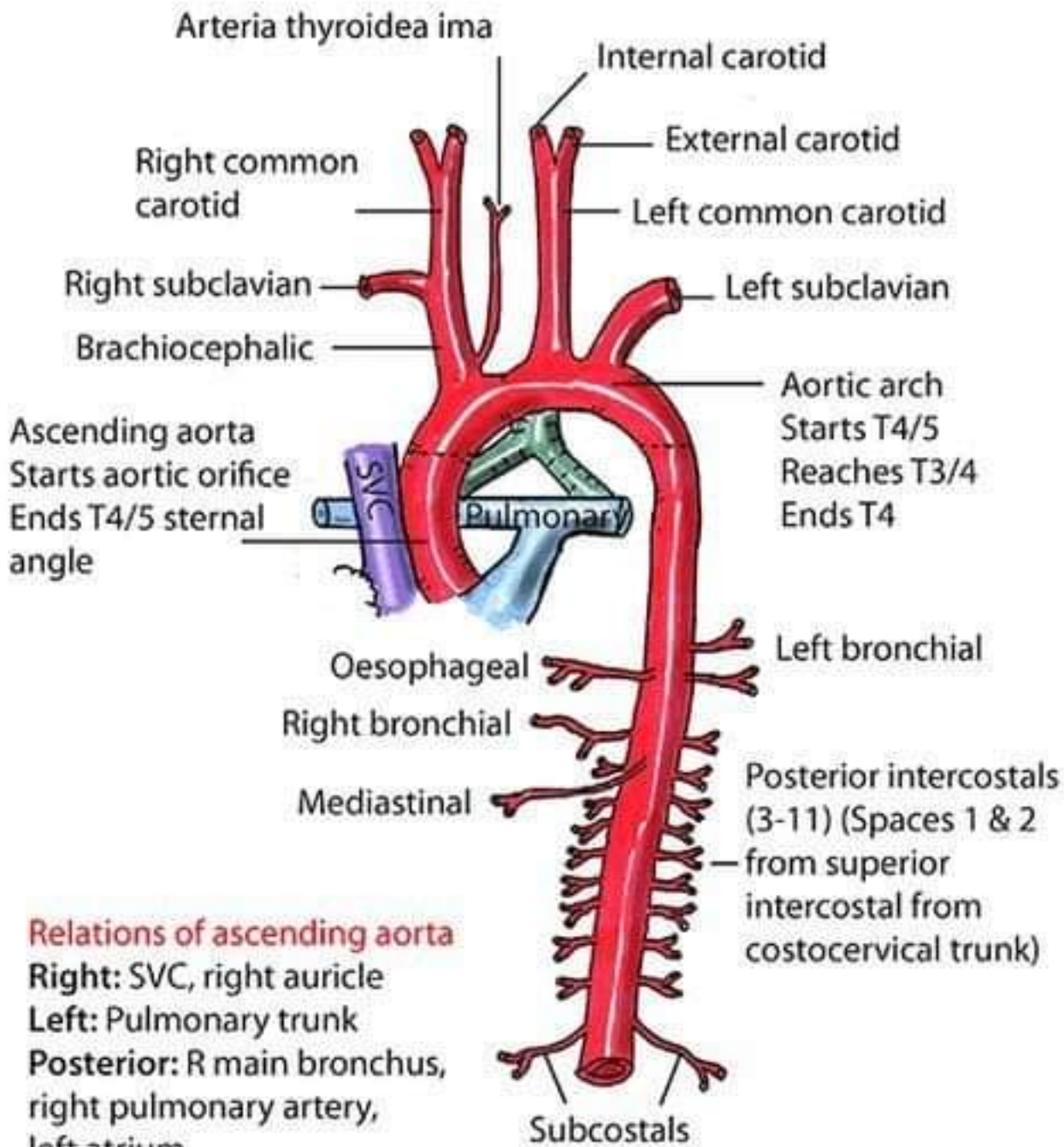
Heart and Blood Circulation System







THORACIC AORTA



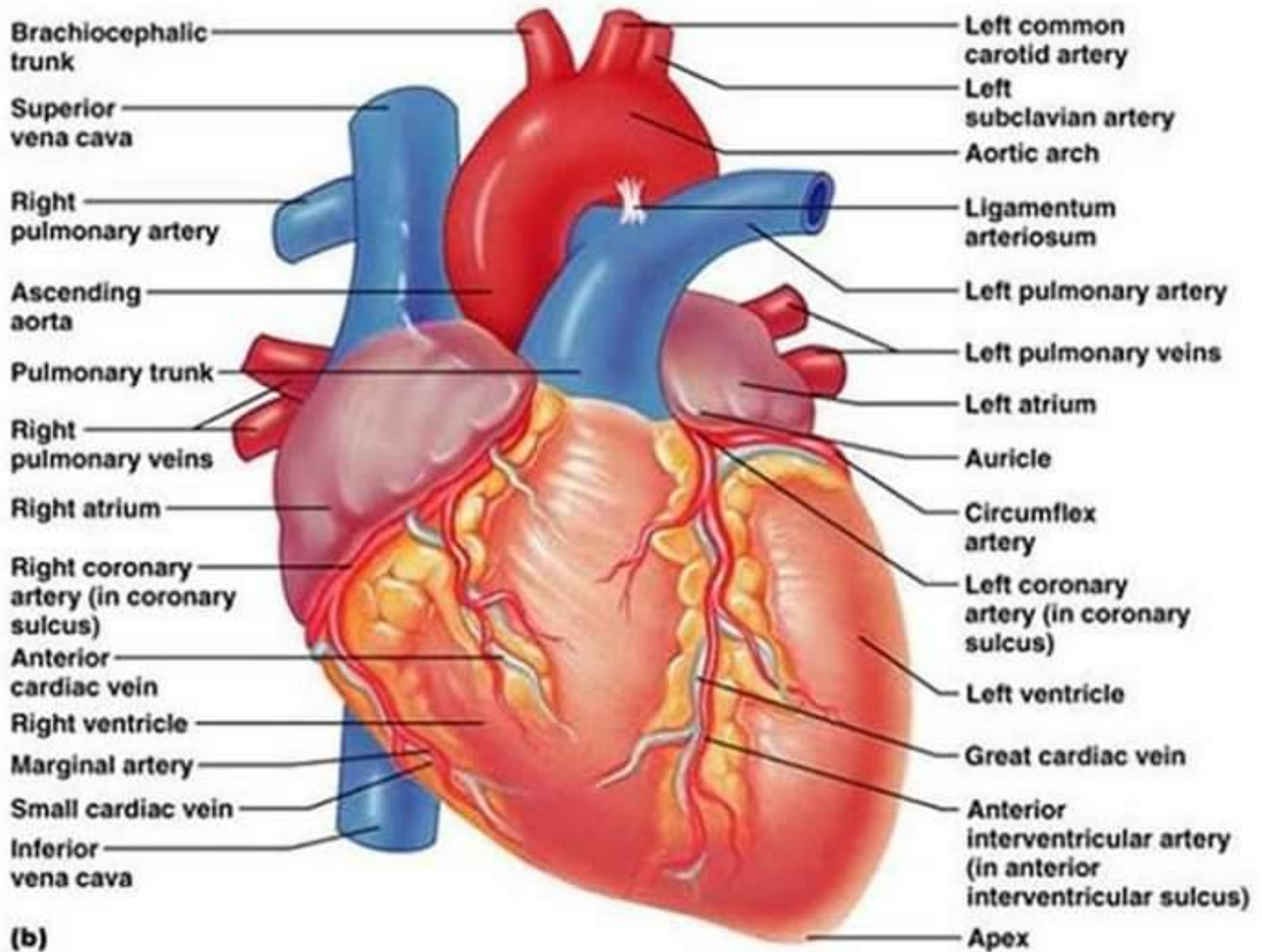
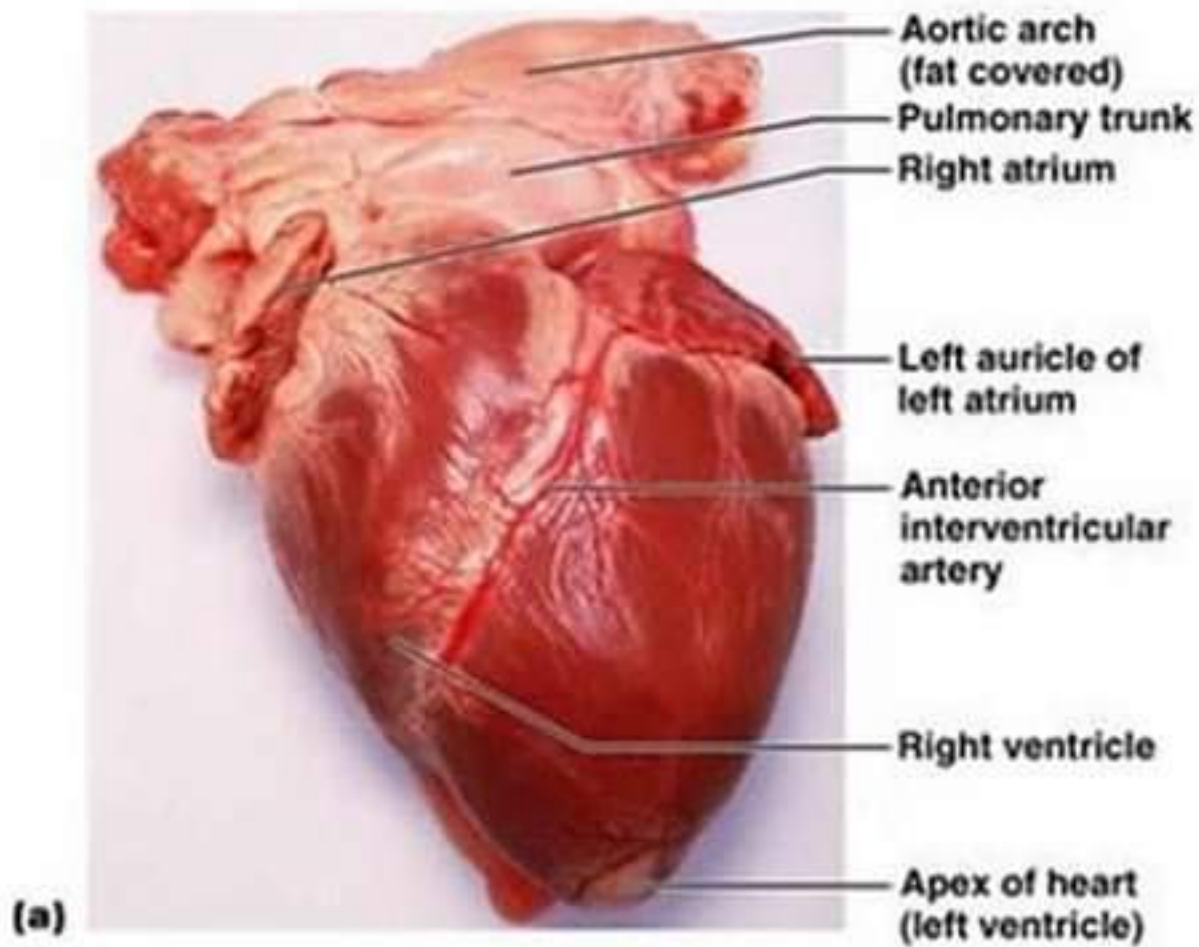
Relations of ascending aorta

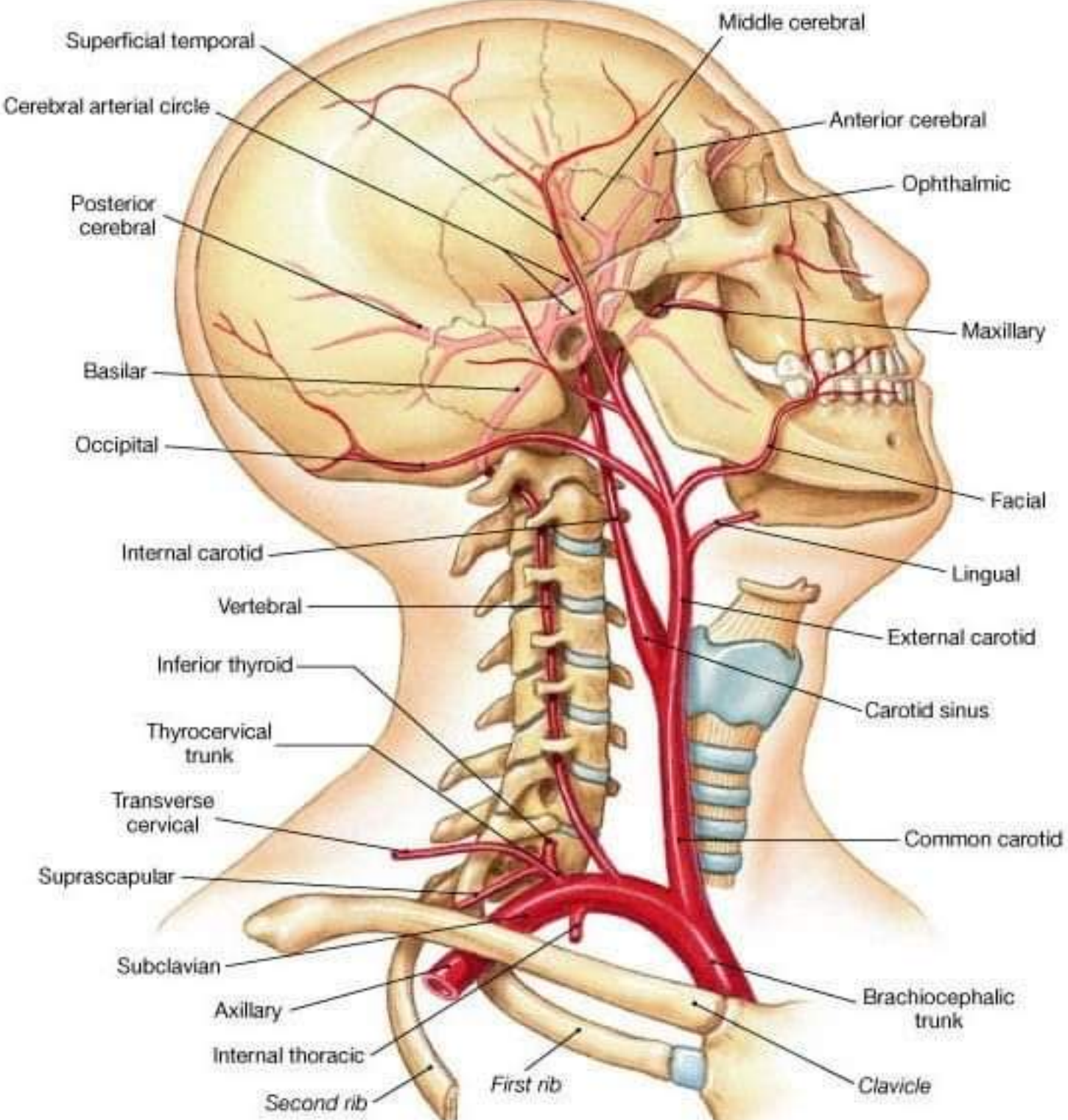
Right: SVC, right auricle

Left: Pulmonary trunk

Posterior: R main bronchus, right pulmonary artery, left atrium

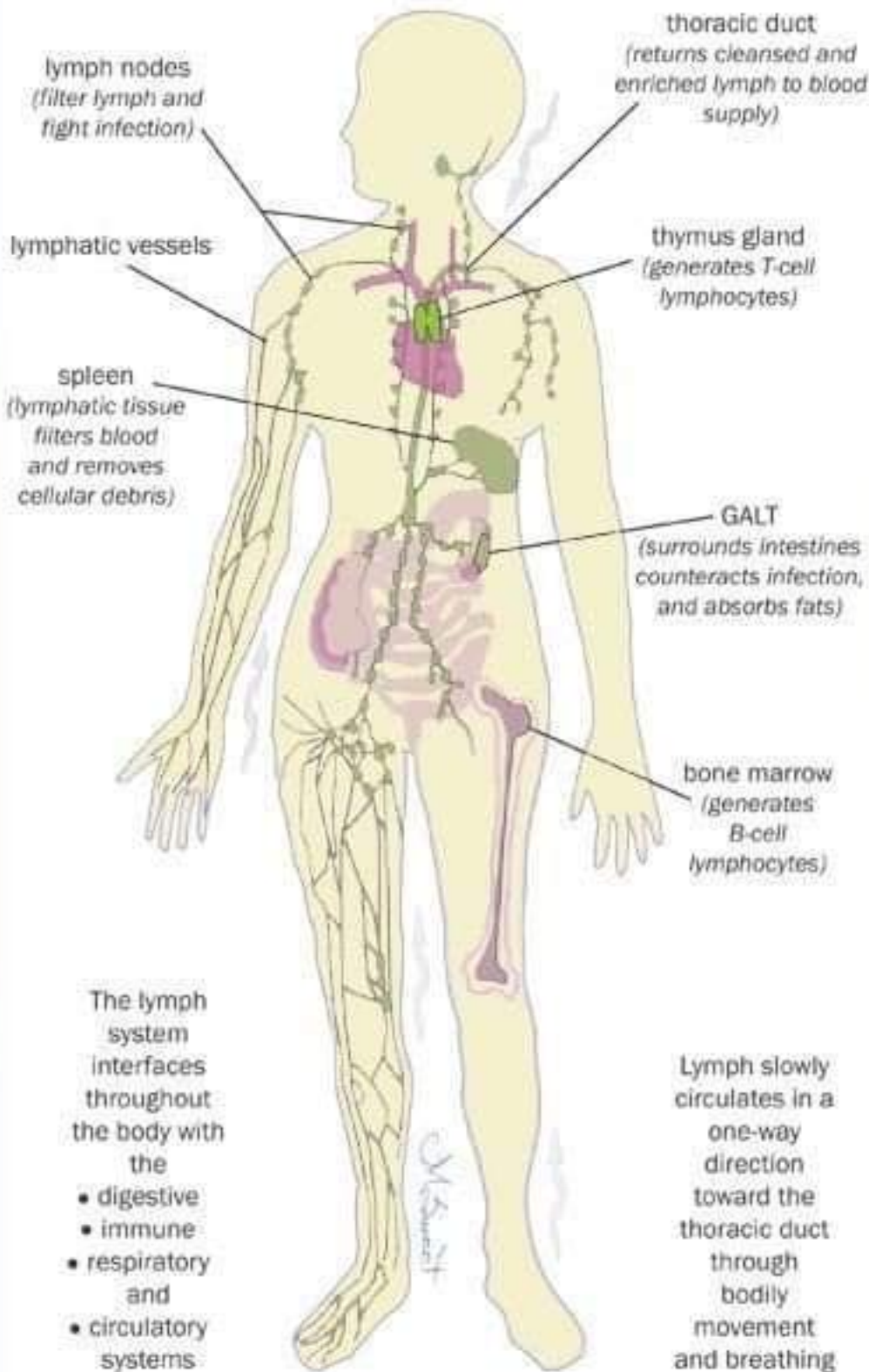
Anterior: Sternum, pulmonary trunk, infundibulum of right ventricle

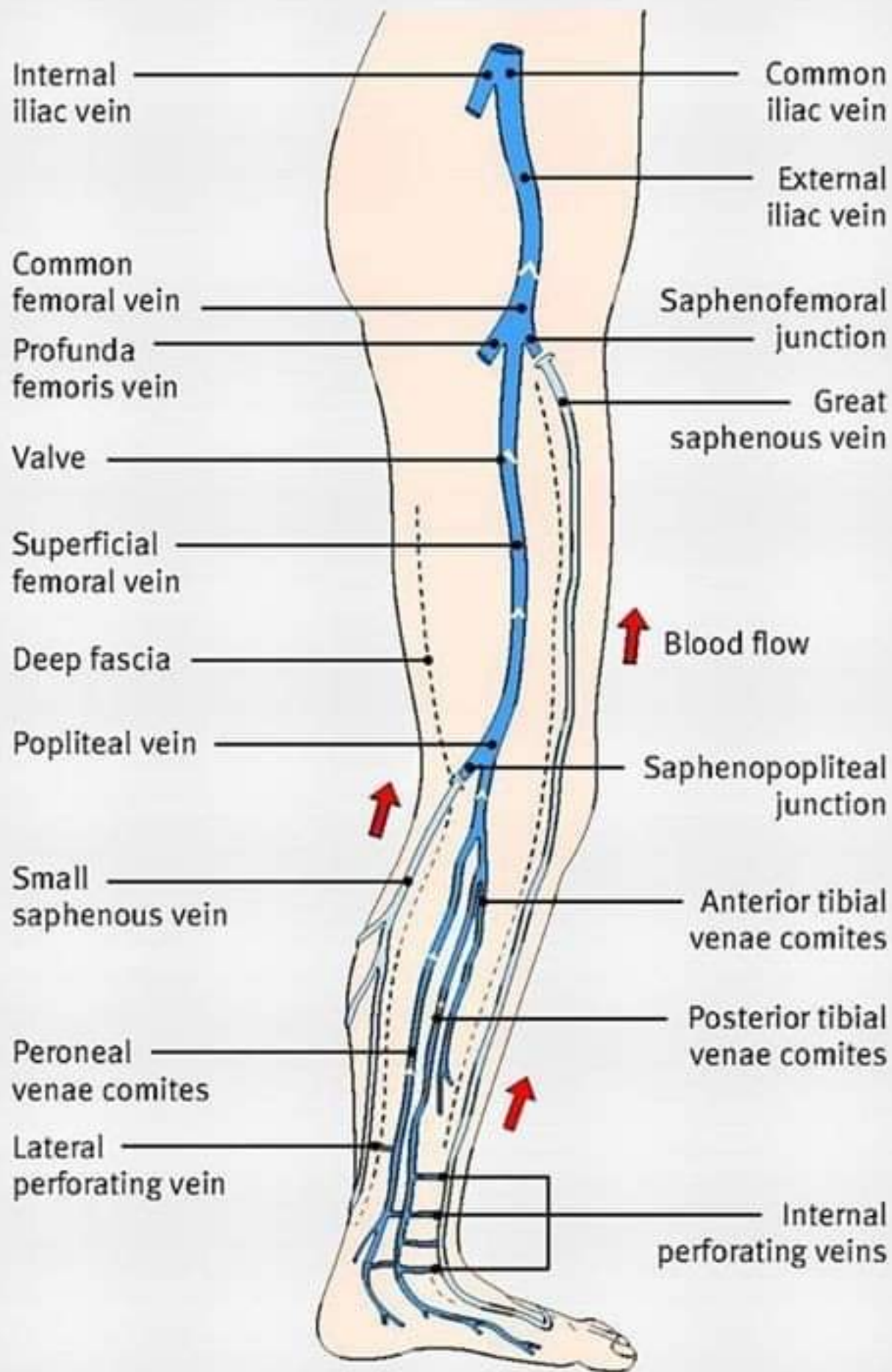




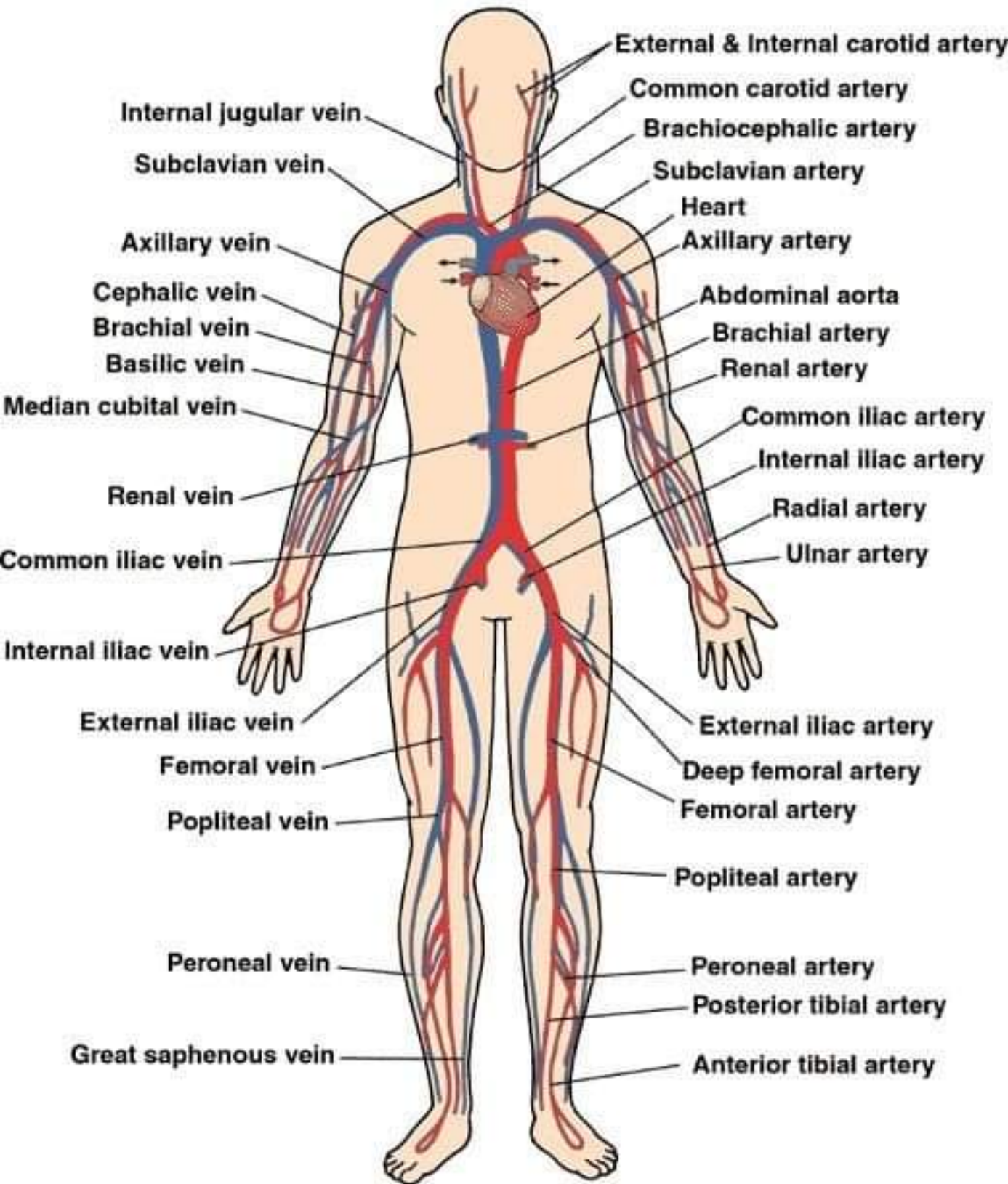
(a) Arteries of neck and head, an oblique lateral view from the right side

Lymphatic System

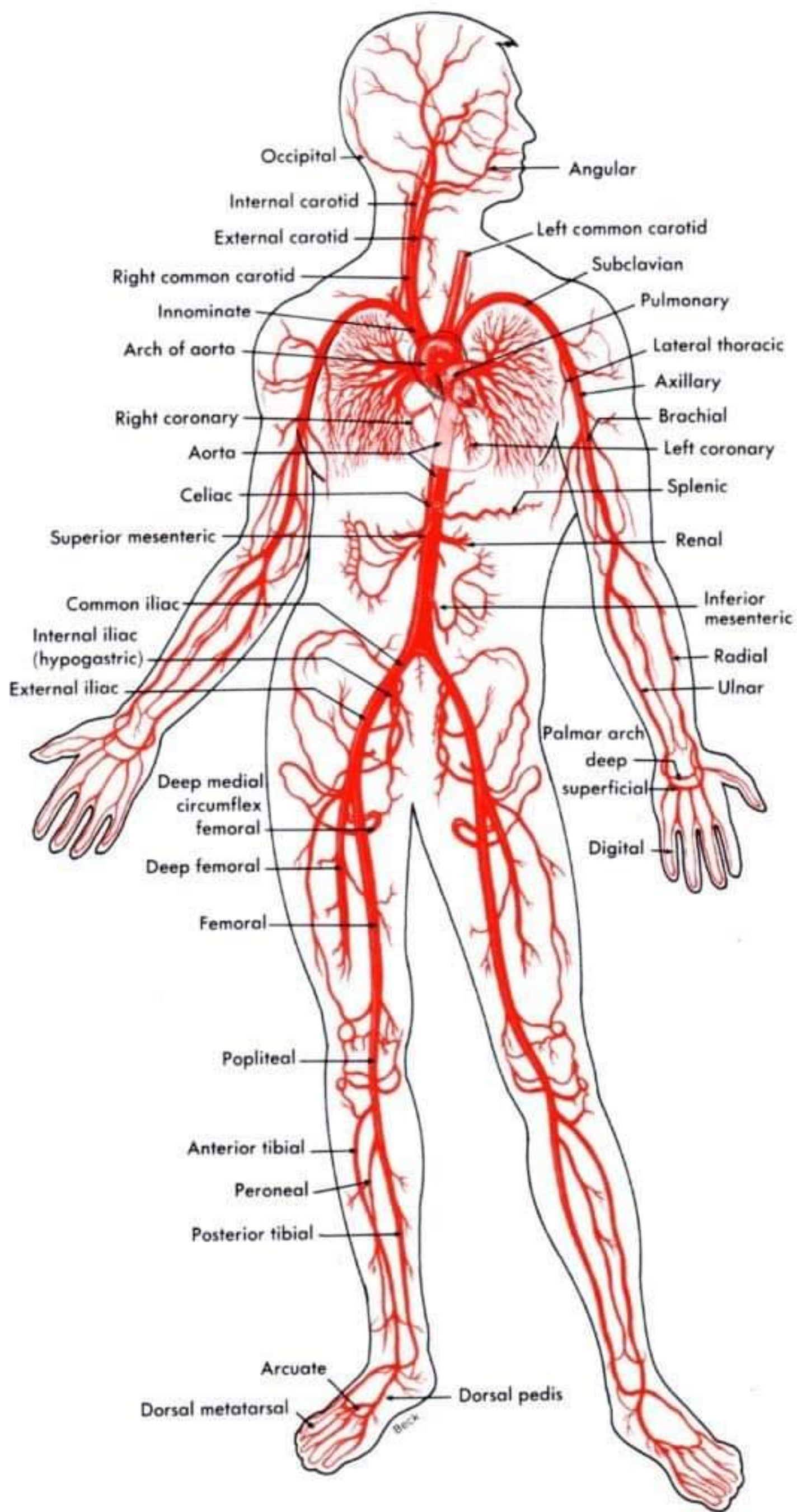




Circulatory System



arteries of the body



Arterial and Venous Circulation of the Legs

