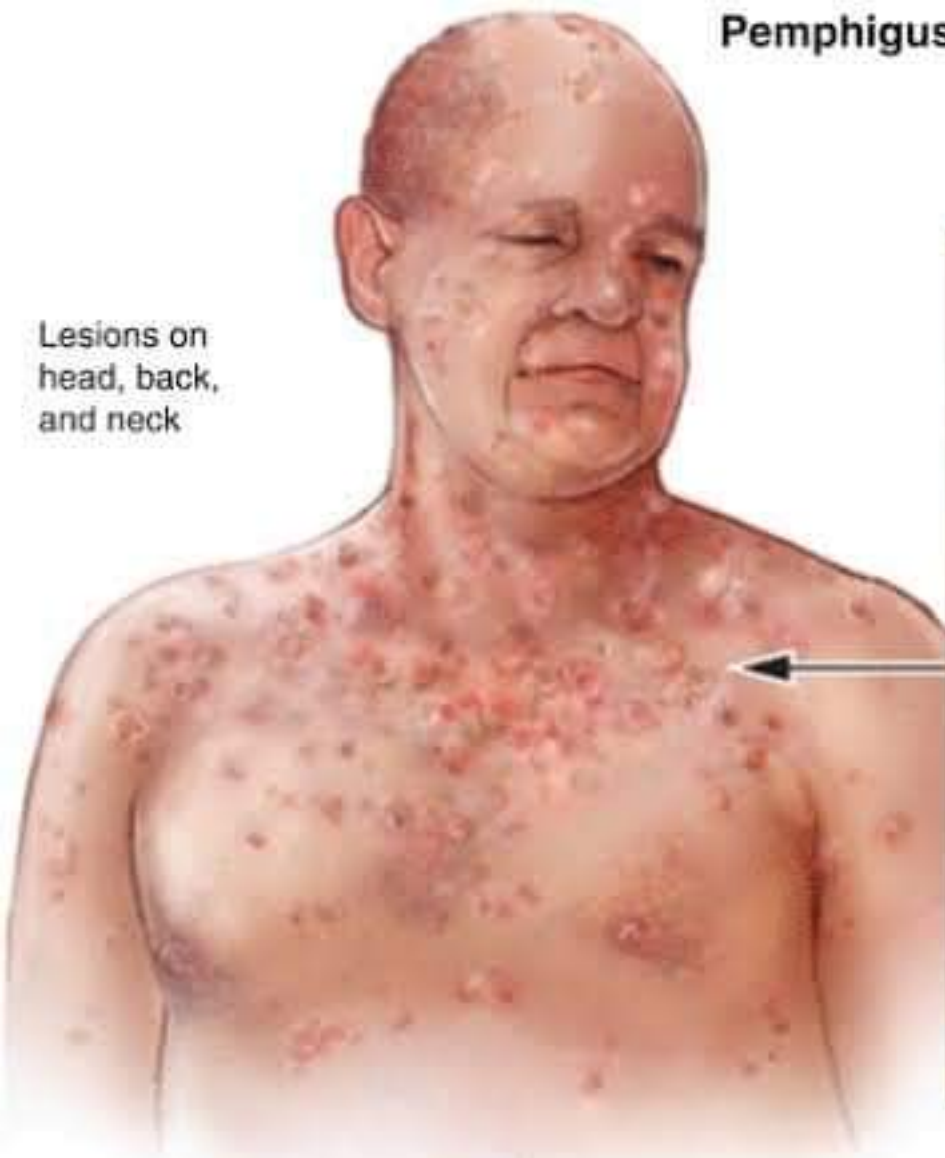
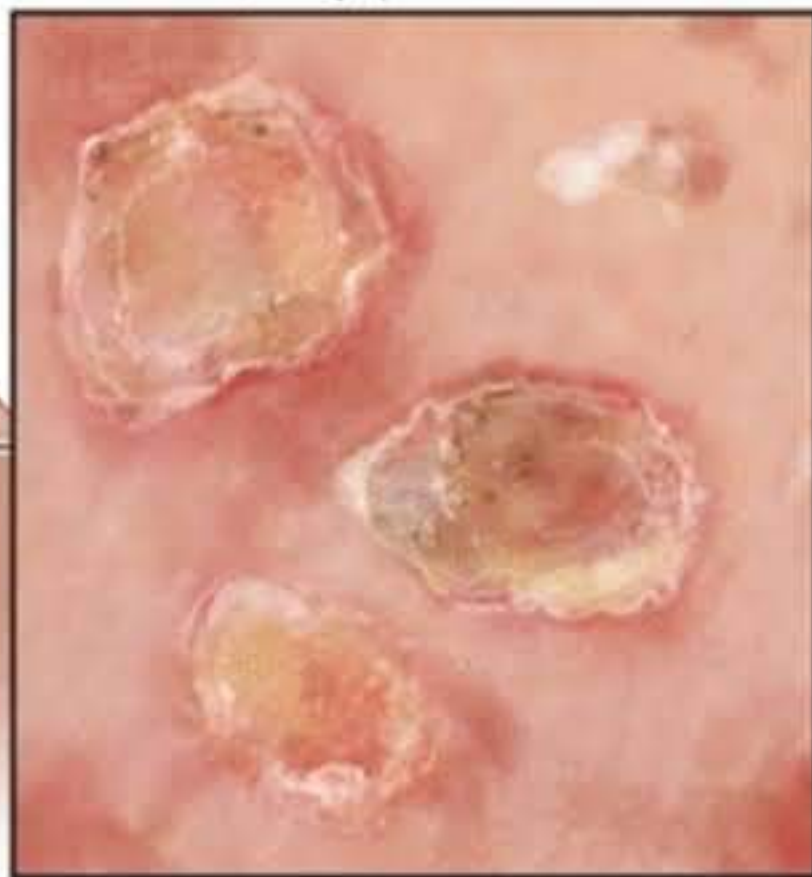

Pemphigus foliaceus

Lesions on
head, back,
and neck

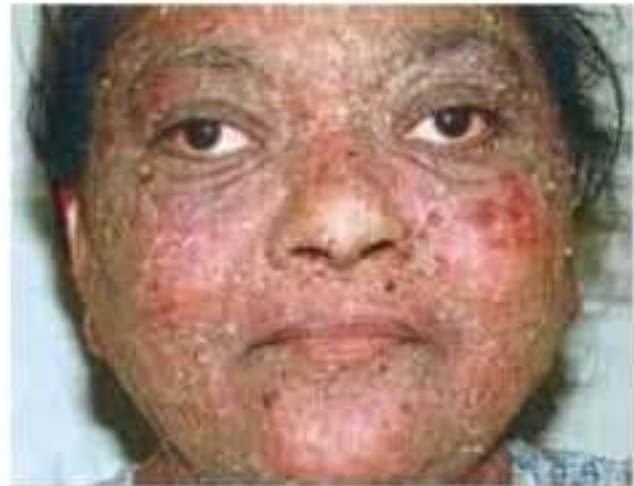
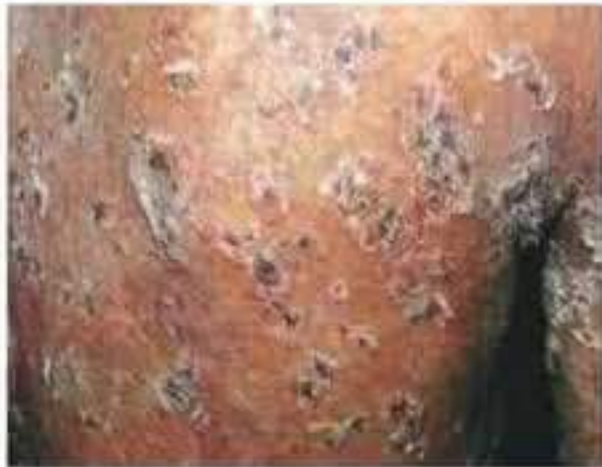
Red, crusty spots on skin



Pemphigus Foliaceus

- Pemphigus foliaceus (PF) is characterized by small flaccid bullae with crusting and scaling.
- The initial lesions are scaly papules or superficial flaccid bullae on normal or erythematous skin.



Pemphigus foliaceus

- Etiology
 - Autoantibodies against Dsg1
 - Rarely Ab shift → later are formed against Dsg3 and patient develops PV
 - More often drug-induced than PV
 - Drugs with sulfhydryl groups
 - Mechanism might be interference to adhesion molecules, modification of antigenicity and regulation of immune response
 - May be caused by sunburn or as paraneoplastic sign

Physical Exam

- ▶ Skin: Thick, greasy yellow scale present over face. Crusted ulcerations on scalp and torso. A few bullae located on chest.

